

## Devices for the endoscopic treatment of hemorrhoids

*The ASGE Technology Committee provides reviews of existing, new, or emerging endoscopic technologies that have an impact on the practice of GI endoscopy. Evidence-based methodology is used, performing a MEDLINE literature search to identify pertinent clinical studies on the topic and a MAUDE (U.S. Food and Drug Administration Center for Devices and Radiological Health) database search to identify the reported complications of a given technology. Both are supplemented by accessing the “related articles” feature of PubMed and by scrutinizing pertinent references cited by the identified studies. Controlled clinical trials are emphasized, but in many cases data from randomized, controlled trials are lacking. In such cases, large case series, preliminary clinical studies, and expert opinions are used. Technical data are gathered from traditional and Web-based publications, proprietary publications, and informal communications with pertinent vendors. Technology Status Evaluation Reports are drafted by 1 or 2 members of the ASGE Technology Committee, reviewed and edited by the Committee as a whole, and approved by the Governing Board of the ASGE. When financial guidance is indicated, the most recent coding data and list prices at the time of publication are provided. For this review, the MEDLINE database was searched through February 2013 for relevant articles by using the key words “endoscopic treatment of hemorrhoids,” “hemorrhoid therapy,” “rubber band ligation,” “infrared coagulation,” “bipolar diathermy,” “injection sclerotherapy,” “Doppler guided laser photocoagulation,” and “cryotherapy.” Technology Status Evaluation Reports are scientific reviews provided solely for educational and informational purposes. Technology Status Evaluation Reports are not rules and should not be construed as establishing a legal standard of care or as encouraging, advocating, requiring, or discouraging any particular treatment or payment for such treatment.*

### BACKGROUND

Hemorrhoids are pathologically dilated vascular sinuoids in the anal canal that can cause rectal bleeding, pruritus, and pain. The pathogenesis of hemorrhoids remains controversial; vascular congestion (eg, prolonged sitting, pregnancy) and mucosal prolapse (eg, caused by aging or

constipation/straining) may play a role. The most widely accepted theory is that they result from destructive changes to the supporting connective tissue.<sup>1</sup> It has been estimated that more than 50% of adults greater than 50 years of age in the United States have experienced symptoms due to hemorrhoids.<sup>2</sup> Internal hemorrhoids are graded based on protrusion and reducibility (Table 1). External hemorrhoids are not graded. When medical treatment fails, most patients with symptomatic grade I, II, and III internal hemorrhoids may be treated with office-based procedures.<sup>3</sup> Surgical therapy is usually reserved for patients with larger grade IV hemorrhoids that may be refractory to medical therapy or office procedures.<sup>4,5</sup> This report provides an overview of equipment used in the endoscopic treatment of internal hemorrhoids.

### TECHNOLOGY UNDER REVIEW

Several techniques are available for nonsurgical treatment of hemorrhoids, all with the goal of causing fibrosis, retraction, and fixation of the hemorrhoidal cushions. These techniques include rubber band ligation (RBL), infrared coagulation (IRC), bipolar diathermy, laser photocoagulation, injection sclerotherapy, and cryotherapy. Nonsurgical treatment of hemorrhoids is generally done in the office or endoscopy suite. Patients are usually unsedated to allow for patient feedback from inadvertent treatment below the dentate line. Patients may be in the jackknife position or in the left lateral decubitus position with the right knee drawn up. No bowel preparation is required.

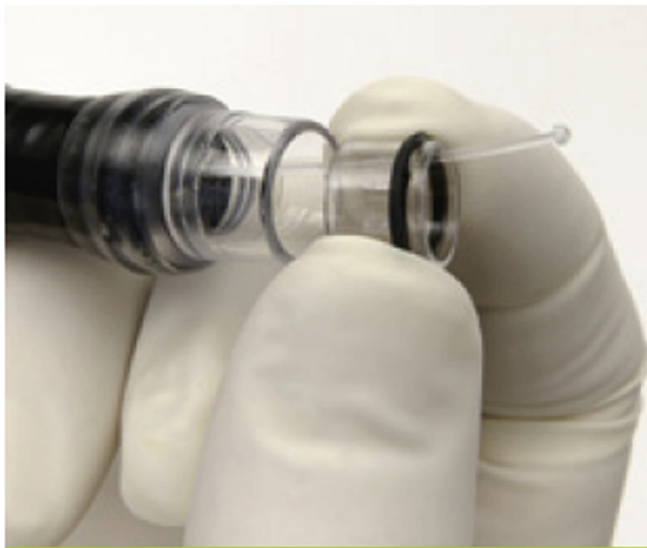#### Rubber band ligation

Considered the most popular nonsurgical intervention in the treatment of grade I and II hemorrhoids, RBL can be performed with or without an endoscope.<sup>6</sup>

**Endoscopic RBL.** Endoscopic band ligation devices comprise a transparent plastic cap with preloaded bands that fits on the tip of an endoscope. Suction or forceps are used to capture and position the hemorrhoid before placement of a small-diameter circular band around the base of the tissue. A trip-wire or string runs from the cap to the endoscope handle via the accessory channel, and, when tightened by rotating a retracting spool fixed to the biopsy port, shortening of the string causes band deployment around the hemorrhoidal cushion.<sup>7</sup> Placement of the band causes ischemic necrosis, ulceration, and scarring, which result in fixation of the connective tissue

**TABLE 1. Grading system for internal hemorrhoids**

Grade	
I	Prominent hemorrhoidal vessels with bleeding, but without prolapse
II	Prolapse, reduces spontaneously
III	Prolapse, requiring manual reduction
IV	Prolapse, not reducible

**Figure 1.** Stiegman-Goff Bandito Ligator. Photo courtesy of ConMed Endoscopic Technologies.

to the rectal wall.<sup>8</sup> This technique is similar to the banding of esophageal varices, except that it is often performed in retroflexion. The only device specifically marketed for endoscopic band ligation of hemorrhoids is the Stiegmann-Goff Bandito Endoscopic Hemorrhoidal Ligator (ConMed Corp, Utica, NY), which fits on a 13- to 15-mm endoscope (Fig. 1). Standard endoscopic variceal band ligation devices have been used as well.<sup>9-12</sup>

**RBL without an endoscope.** The ShortShot Saeed Hemorrhoidal Multi-Band Ligator (Cook Medical, Winston-Salem, NC) is a single-use, disposable device designed for use with an anoscope. It is in the shape of a pistol, with a suction tubing port at the base of the handle (Fig. 2). The tip of the ligation device holds 4 preloaded bands and is placed through an anoscope to visualize internal hemorrhoids. Suction is activated by covering a vent on the anterior side of the handle with the index finger after the tip of the ligation device is placed on the hemorrhoid, taking care to remain just above the dentate line. The vessel is suctioned into the ligation device, and a wheel is turned using the thumb, leading to deployment of a band.

**Figure 2.** Shortshot™ Saeed Endoscopic Hemorrhoid Multi-band ligator. Permission for use granted by Cook Medical Incorporated, Bloomington, Indiana.

The CRH O'Regan Disposable Hemorrhoid Banding System (CRH Medical Corp, Vancouver, BC, Canada) is a single-use device consisting of a plastic syringe with a band at its tip (Fig. 3). The plunger on the syringe is retracted to suction the hemorrhoid into the device, and the band pusher is moved forward to deploy the band.<sup>13</sup> The procedure can be performed with a slotted anoscope or by using a “blind” or “touch” technique.

The McGivney Hemorrhoidal Ligator (Miltex, York, Pa) is a stainless steel device advanced through an anoscope that applies latex or latex-free O-rings or bands directly to hemorrhoids with the aid of grasping forceps rather than suction (Fig. 4). The device has a compressible handle and a 7- or 10-inch long shaft that can be rotated to obtain the optimal angle for band placement. Under direct vision, the hemorrhoid is grasped with forceps and traction is applied. The ligator tip is approximated to the hemorrhoid, and the handle is squeezed, causing O-ring deployment. A new O-ring must be manually loaded to the tip of the device for each hemorrhoid treated.

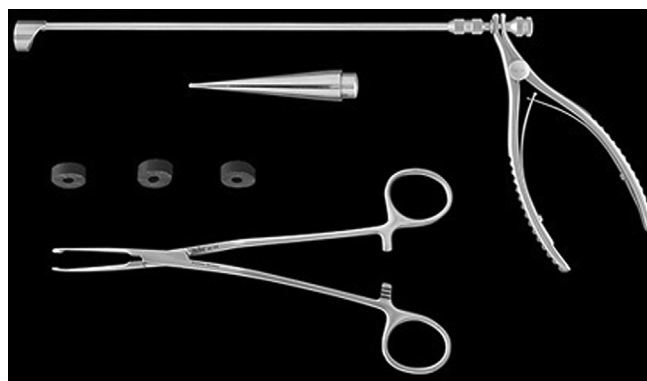
### Infrared coagulation

IRC uses direct application of heat to induce coagulation and fibrosis in the submucosal layer. The Precision Endoscopic Infrared Coagulator (Precision Endoscopic Technologies, Sturbridge, Mass) uses a single-use, 3.2-mm outer diameter, 300 cm long flexible fiberoptic probe that is passed through an endoscope channel. The distal tip of the probe is placed in contact with the hemorrhoid tissue, ideally at the pedicle of the hemorrhoid's 3, 7, and 11 o'clock positions, and short 1- to 5-second bursts of infrared radiation are delivered to by depressing a foot pedal.<sup>14</sup> The procedure can be performed at the time of sigmoidoscopy or colonoscopy in a retroflexed position and is approved by the U.S. Food and Drug Administration (FDA) for treatment of grade I, II, and III internal hemorrhoids.



**Figure 3.** CRH Ligator. Photo courtesy of CRH Medical Corporation, and copyright Neal Osborn, MD.

The IRC 2100 (Redfield Corp, Rochelle Park, NJ) is a non-endoscopic system consisting of a compact power unit with a tungsten-halogen lamp.<sup>15</sup> A pistol-shaped hand-held applicator connects to the power unit, and a quartz glass light guide extends out from the shaft. The light guide has an



**Figure 4.** The McGivney Hemorrhoidal Ligator. Permission granted by Integra Miltex, a business of Integra LifeSciences Corporation, Plainsboro, New Jersey, USA.

angled tip that is applied gently to the mucosa just superior to the enlarged cushion for 1 to 1.5 seconds. Infrared light is converted to heat, resulting in coagulation and necrosis with subsequent fibrosis of the submucosa.

The Lumatec Infrared Coagulator (Lumatec, Munich, Germany) is similar to the IRC 2100. It is composed of a hand piece, an infrared radiator power source, a rigid quartz glass light guide, and a tissue contact surface made from a nonadherent Teflon polymer. A low-voltage tungsten-halogen lamp (15 V) produces a beam that travels through the light guide to the tissue. It is activated with a trigger device on the hand piece. This device is not available in the United States.

### Bipolar diathermy

Bipolar diathermy, also known as bipolar electrotherapy and BICAP (bipolar circumactive probe), was first described in 1987 as a treatment for hemorrhoids. High-frequency electrical current is applied by a probe or forceps under direct vision in 1- to 2-second bursts. This causes coagulation and tissue destruction, leading to fibrosis in the submucosal layer.<sup>16</sup> Most studies of bipolar coagulation therapy of hemorrhoids use a rigid probe (previously Circon ACMI, Stamford Conn; new manufacturer, ConMed Corp) through a slotted anoscope.<sup>8</sup> Although most endoscopists are familiar with the use of bipolar cautery techniques, bipolar treatment of hemorrhoids by using a standard 10F or 7F BICAP probe through an endoscope has not been studied, and the technique has largely been replaced by RBL.

### Injection sclerotherapy

Injection of a sclerosing agent has been used to treat hemorrhoids, usually grade I or II. A sclerotherapy needle is passed through the endoscope or anoscope, and 1 to 3 mL of sclerosant is injected into the submucosa at the base of the hemorrhoid (rather than intravascularly). This causes an inflammatory response and fibrosis that interrupt blood flow. The use of a variety of sclerosing agents has been historically described, including ethanalamine, quinine, and

hypertonic saline solution, but the most commonly used agent is 5% phenol in oil.<sup>5,17,18</sup> Recently, a newer sclerosing agent composed of aluminum potassium sulfate and tannic acid (ALTA) has been reported in Japan.<sup>19</sup> This agent has been used to treat grade III hemorrhoids. Its use is not FDA approved in the United States.

### Doppler-guided laser photocoagulation

The HeLP system (Biolitec AG, Jena, Germany) uses a 980-nm laser diode to deliver energy. Two probes, a 1000- $\mu$ m disposable laser fiber and a disposable 3-mm, 20-MHz Doppler probe, are passed through a specially designed proctoscope. The Doppler probe allows identification of the branches of the superior hemorrhoidal arteries that supply blood to the hemorrhoids, and laser energy is then applied in a pulsed fashion, resulting in photocoagulation of the arterial branches and fixation of the rectal mucosa and submucosa to the muscular layer. The individual products, including the laser and probe, are available for general surgical applications; however, the system as a whole is not currently FDA approved for the treatment of hemorrhoids in the United States.

### Cryotherapy

Cryotherapy uses special probes through which cooled liquid nitrogen or nitrous oxide is delivered to hemorrhoidal tissue, causing necrosis and destruction of the tissue. Prolonged postprocedure symptoms (eg, anal leakage, pain) have been reported, and this technique has largely been abandoned.<sup>20</sup>

### Outcomes and comparative data

**RBL versus IRC and sclerotherapy.** RBL has been prospectively compared with IRC. Most studies showed equivalent long-term success, although 2 found RBL to be significantly more effective.<sup>21-25</sup> These studies demonstrated long-term control of symptoms in 59% to 97% of patients after RBL compared with 81% to 98% after IRC. However, RBL had higher immediate postprocedure bleeding rates and patient discomfort.

A meta-analysis of 18 randomized, controlled trials comparing 2 or more treatments for hemorrhoids (hemorrhoidectomy, sclerotherapy, RBL, and IRC) showed that RBL was superior compared with sclerotherapy for all grades of hemorrhoids ( $P = .005$ ), with no difference in complication rates, and required fewer treatment sessions compared with sclerotherapy and IRC.<sup>26</sup>

**RBL versus other methods.** RBL was compared with Doppler-guided laser photocoagulation (DLC) in a randomized trial of 60 patients.<sup>27</sup> Postprocedure pain scores were lower for DLC ( $P < .001$ ), and at 6-month follow-up, 90% of DLC patients were symptom free compared with 53% of RBL patients ( $P < .001$ ). Overall satisfaction was reported as 75% for RBL and 90% for DLC. There was no difference in bleeding rates, but tenesmus and

mild urinary retention were reported in 4 RBL patients but no DLC patients ( $P < .001$ ).

RBL has been compared with bipolar electrocoagulation in a randomized, prospective study of 45 patients with grade II or III hemorrhoids.<sup>8</sup> RBL led to symptom control with fewer treatments ( $2.3 \pm 0.2$  vs  $3.8 \pm 0.4$ ;  $P < .05$ ), and had a higher success rate (92% vs 62%;  $P < .05$ ). Symptomatic recurrence at 1 year was similar.

**RBL by using rigid versus flexible endoscopy.** A randomized, controlled trial of 100 patients found that fewer treatment sessions ( $P < .01$ ) and fewer bands were required ( $P < .01$ ) by using endoscopically applied band ligation compared with ligation by using rigid proctoscopy.<sup>28</sup> No significant differences were noted in postligation bleeding requiring intervention, analgesic medication requirement, or recurrent bleeding at 12-month follow-up. A smaller randomized, prospective study ( $N = 41$ ) comparing RBL performed by using rigid proctoscopy and flexible endoscopy found that post-ligation pain was more common in the flexible endoscopy group (3 vs 10 patients,  $P < .05$ ).<sup>29</sup> However, more bands were placed per patient in the flexible endoscopy group.

**Comparison of different methods of RBL.** A prospective, randomized trial of 100 consecutive patients with grade II and III hemorrhoids compared the use of suction band ligation with forceps-assisted band ligation. Immediate and postprocedure pain was more severe in the forceps group on a visual analogue scale (6.08 vs 3.08,  $P < .001$ ). Intraprocedure bleeding occurred in 25 patients in the forceps group versus 5 in the ligator group ( $P < .001$ ).<sup>30</sup>

Two prospective, randomized trials<sup>31,32</sup> compared RBL of single versus multiple hemorrhoids per treatment session. Both approaches were effective, and no differences in morbidity were detected.

Retroflexed endoscopic band ligation has been evaluated as an alternative method to conventional forward-viewing RBL, but the 2 techniques have not been directly compared.<sup>33,34</sup>

**Sclerotherapy, bipolar diathermy, IRC.** A trial of 102 patients randomized to treatment with either IRC or bipolar diathermy showed no difference in complications or number of treatments required.<sup>35</sup> A randomized study of 102 patients compared sclerotherapy versus bipolar electrocoagulation. This trial demonstrated that electrocoagulation was more painful, but was more effective in reducing bleeding ( $P = .039$ ).<sup>36</sup>

Multiple studies have examined the use of ALTA as a sclerosant. A noncomparative study found success rates of higher than 97% at 28 days for grade II to IV hemorrhoids after injection of ALTA; the recurrence rate was 18.3% at 2 years.<sup>37</sup> Two retrospective studies ( $N = 1210$  and  $N = 165$ ) comparing ALTA with surgical hemorrhoidectomy showed that ALTA injection had recurrence rates of 3.6% to 16% versus 0% to 2% in surgical patients with follow-up of 6 to 45 months.<sup>19,38</sup>

**TABLE 2. Hemorrhoid banding devices**

Name	Manufacturer	Cost	Additional Info
Stiegmann-Goff Bandito Endoscopic Hemorrhoid Ligator	ConMed	\$373.40 per box	5 kits/box, each kit includes 1 trip wire, 1 friction fit adaptor for 13- to 15-mm anoscope, and 3 clear cylinders, each loaded with a single band
ShortShot Saeed Hemorrhoidal Multi-Band Ligator	Cook Medical	\$50	Disposable, preloaded with 4 bands
McGivney Hemorrhoidal Ligator	Miltex	\$590	Includes 100 O-rings
CRH O'Regan Disposable Hemorrhoid Banding System	CRH Medical Corp	\$65	
Precision Endoscopic Infrared Coagulator	Precision Endoscopic Technologies	\$4995	Box of 10 probes \$1200
IRC 2100	Redfield Corp	\$8995	
Lumatec Infrared Coagulator	Lumatec	No pricing available	Not available in the United States
HeLP (Hemorrhoid Laser Procedure)	Biolitec	No pricing available	Equipment is available in the United States, but not currently FDA approved for hemorrhoid treatment

### Surgical versus endoscopic treatment

A meta-analysis compared 18 randomized trials that studied various methods of hemorrhoidal therapy.<sup>39</sup> Overall, patients undergoing surgical hemorrhoidectomy had a significantly better response than those undergoing treatment with RBL (odds ratio 0.17 for no response, favoring surgical hemorrhoidectomy,  $P = .001$ ). However, a significantly greater risk of complications and pain was noted with surgical therapy ( $P = .02$ ).

A Cochrane Review included 3 randomized, controlled trials comparing RBL with excisional hemorrhoidectomy.<sup>6</sup> Hemorrhoidectomy achieved a better overall cure rate for grade III hemorrhoids (2 trials, 116 patients; relative risk 1.23; 95% CI, 1.04-1.45;  $P = .01$ ), but no significant difference was noted for grade II hemorrhoids.

### SAFETY

Nonsurgical treatment of hemorrhoids is generally considered to be safe. A large retrospective review of 7850 patients, all of whom were treated with a standard combination of sclerotherapy, RBL, and IRC reported mild to moderate pain in 22.6%, severe pain in 2.2%, mild hemorrhage in 2.5%, urinary retention in 0.1%, and hemorrhage requiring transfusion in 0.1%.<sup>40</sup> A report of 500 consecutive patients undergoing RBL revealed no cases of pelvic sepsis and no admissions for bleeding after the procedure.<sup>41</sup>

Rare serious adverse events have been reported with nonsurgical hemorrhoid treatments, including perineal sepsis, retroperitoneal gas and edema, bacteremia, epididymitis, rectal perforation, and abscesses of the liver, prostate, and seminal vesicle.<sup>42-46</sup>

### EASE OF USE

Although the endoscopic methods of band ligation, injection therapy, and bipolar cautery are familiar to most gastroenterologists, application of these techniques in the anorectal area to hemorrhoids is not part of many training programs. Knowledge of anorectal anatomy, proper patient selection, and the management of immediate and delayed adverse events are essential.

### FINANCIAL CONSIDERATIONS

The costs of devices described in this article are listed in Table 2. Hemorrhoidal therapy can be billed by using Current Procedural Terminology codes for hemorrhoidectomy, internal, by rubber band ligation(s) (46221) and destruction of internal hemorrhoid(s) by thermal energy (eg, infrared coagulation, cautery, radiofrequency) (46930). Sigmoidoscopy (45330-45345), colonoscopy (45378-45392), or anoscopy (46600) codes may also be billed as indicated.

### AREAS FOR FUTURE RESEARCH

Research is needed to compare the degree of benefit of endoscopic therapy over medical management. Although the data suggest that office-based techniques such as RBL and IRC are effective and safe for symptomatic grade I and II hemorrhoids, the procedures are not commonly performed by gastroenterologists. Research is needed to examine the barriers that prevent or discourage gastroenterologists from performing these techniques. Further

prospective trials comparing DLC and sclerotherapy with ALTA with surgical treatment are warranted.

## SUMMARY

Multiple endoscopic methods are available to treat symptomatic internal hemorrhoids. Because of its low cost, ease of use, low rate of adverse events, and relative effectiveness, RBL is currently the most widely used technique.

## DISCLOSURE

*All authors disclosed no financial relationships relevant to this publication.*

*Abbreviations: ALTA, aluminum potassium sulfate and tannic acid; DLC, Doppler-guided laser photocoagulation; FDA, U.S. Food and Drug Administration; IRC, infrared coagulation; RBL, rubber band ligation.*

## REFERENCES

- Thomson WH. The nature of haemorrhoids. *Br J Surg* 1975;62:542-52.
- Johanson JF, Sonnenberg A. The prevalence of hemorrhoids and chronic constipation. An epidemiologic study. *Gastroenterology* 1990;98:380-6.
- Rivadeneira DE, Steele SR, Ternent C, et al. Practice parameters for the management of hemorrhoids (revised 2010). *Dis Colon Rectum* 2011;54:1059-64.
- Cataldo P, Ellis N, Gregorczyk S, et al. Practice parameters for the management of hemorrhoids (revised). *Dis Colon Rectum* 2005;48:189-94.
- Kaidar-Person O, Person B, Wexner SD. Hemorrhoidal disease: a comprehensive review. *J Am Coll Surg* 2007;204:102-17.
- Shanmugam V, Thaha MA, Rabindranath KS, et al. Rubber band ligation versus excisional haemorrhoidectomy for haemorrhoids. *Cochrane Database Syst Rev* 2005:CD005034.
- Liu J, Petersen BT, Tierney WM, et al. Endoscopic banding devices. *Gastrointest Endosc* 2008;68:217-21.
- Jutabha R, Jensen DM, Chavalitdhamrong D. Randomized prospective study of endoscopic rubber band ligation compared with bipolar coagulation for chronically bleeding internal hemorrhoids. *Am J Gastroenterol* 2009;104:2057-64.
- Cazemier M, Felt-Bersma RJF, Cuesta MA, et al. Elastic band ligation of hemorrhoids: flexible gastroscop or rigid proctoscope? *World J Gastroenterol* 2007;13:585-7.
- Towers EA, Gang U, Ojo E, et al. Endoscopic hemorrhoidal ligation: preliminary clinical experience. *Gastrointest Endosc* 1998;48:49-52.
- ASGE Technology Committee: Liu J Petersen BT, Tierney WM, Chuttani R, et al. Endoscopic banding devices. *Gastrointest Endosc* 2008;68:217-21.
- Su MY, Chiu CT, Wu CS, et al. Endoscopic hemorrhoidal ligation of symptomatic internal hemorrhoids. *Gastrointest Endosc* 2003;58:871-4.
- Paikos D, Gatopoulou A, Mschos J, et al. Banding hemorrhoids using the O'Regan disposable bander, single center experience. *J Gastrointest Liver Dis* 2007;16:163-5.
- McLemore EC, Rai R, Siddiqui J, et al. Novel endoscopic delivery modality of infrared coagulation therapy for internal hemorrhoids. *Surg Endosc* 2012;26:3082-7.
- Redfield Corporation. Available at: <http://www.redfieldcorp.com/their2100.html>. Accessed April 4, 2013.
- Griffith CD, Morris DL, Ellis I, et al. Out-patient treatment of haemorrhoids with bipolar diathermy coagulation. *Br J Surg* 1987;74:827.
- Graham-Stewart CW. Injection treatment of haemorrhoids. *Br Med J* 1962;1:213-6.
- Santos G, Novell JR, Khoury G, et al. Long-term results of large-dose, single-session phenol injection sclerotherapy for hemorrhoids. *Dis Colon Rectum* 1993;36:958-61.
- Hachiro Y, Kunimoto M, Abe T, et al. Aluminum potassium sulfate and tannic acid (ALTA) injection as the mainstay of treatment for internal hemorrhoids. *Surg Today* 2011;41:806-9.
- Traynor OJ, Carter AE. Cryotherapy for advanced haemorrhoids: a prospective evaluation with 2-year follow-up. *Br J Surg* 1984;71:287-9.
- Ambrose NS, Hares MM, Alexander-Williams J, et al. Prospective randomised comparison of photocoagulation and rubber band ligation in treatment of haemorrhoids. *Br Med J (Clin Res Ed)* 1983;286:1389-91.
- Templeton JL, Spence RA, Kennedy TL, et al. Comparison of infrared coagulation and rubber band ligation for first and second degree haemorrhoids: a randomised prospective clinical trial. *Br Med J (Clin Res Ed)* 1983;286:1387-9.
- Poen AC, Felt-Bersma RJ, Cuesta MA, et al. A randomized controlled trial of rubber band ligation versus infra-red coagulation in the treatment of internal haemorrhoids. *Eur J Gastroenterol Hepatol* 2000;12:535-9.
- Marques CF, Nahas SC, Nahas CS, et al. Early results of the treatment of internal hemorrhoid disease by infrared coagulation and elastic banding: a prospective randomized cross-over trial. *Tech Coloproctol* 2006;10:312-7.
- Gupta PJ. Infrared coagulation versus rubber band ligation in early stage hemorrhoids. *Braz J Med Biol Res* 2003;36:1433-9.
- MacRae H, McLeod R. Comparison of hemorrhoidal treatments: a meta-analysis. *Can J Surg* 1997;40:14-7.
- Giamundo P, Salfi R, Geraci M, et al. The hemorrhoid laser procedure technique vs rubber band ligation: a randomized trial comparing 2 mini-invasive treatments for second- and third-degree hemorrhoids. *Dis Colon Rectum* 2011;54:693-8.
- Wehrmann T, Riphaut A, Feinstein J, et al. Hemorrhoidal elastic band ligation with flexible videoendoscopes: a prospective, randomized comparison with the conventional technique that uses rigid proctoscopes. *Gastrointest Endosc* 2004;60:191-5.
- Cazemier M, Felt-Bersma RJ, Cuesta MA, et al. Elastic band ligation of hemorrhoids: flexible gastroscop or rigid proctoscope? *World J Gastroenterol* 2007;13:585-7.
- Ramzisham AR, Sagap I, Nadeson S, et al. Prospective randomized clinical trial on suction elastic band ligation versus forceps ligator in the treatment of haemorrhoids. *Asian J Surg* 2005;28:241-5.
- Poon GP, Chu KW, Lau WY, et al. Conventional vs. triple rubber band ligation for hemorrhoids. A prospective, randomized trial. *Dis Colon Rectum* 1986;29:836-8.
- Khubchandani IT. A randomized comparison of single and multiple rubber band ligations. *Dis Colon Rectum* 1983;26:705-8.
- Berkelhammer C, Moosvi SB. Retroflexed endoscopic band ligation of bleeding internal hemorrhoids. *Gastrointest Endosc* 2002;55:532-7.
- Fukuda A, Kajiyama T, Arakawa H, et al. Retroflexed endoscopic multiple band ligation of symptomatic internal hemorrhoids. *Gastrointest Endosc* 2004;59:380-4.
- Dennison A, Whiston RJ, Rooney S, et al. A randomized comparison of infrared photocoagulation with bipolar diathermy for the outpatient treatment of hemorrhoids. *Dis Colon Rectum* 1990;33:32-4.
- Khan N, Malik MA. Injection sclerotherapy versus electrocoagulation in the management outcome of early haemorrhoids. *J Pak Med Assoc* 2006;56:579-82.
- Takano M, Iwadare J, Takamura H, et al. A novel sclerosing agent for noninvasive treatments of internal hemorrhoids and pro-lapse. Proceedings of the Annual Meeting of 2010 American Society of Colon and Rectal Surgeons (ASCRS) 2010:s52-54.
- Takano M, Iwadare J, Ohba H, et al. Sclerosing therapy of internal hemorrhoids with a novel sclerosing agent. Comparison with ligation and excision. *Int J Colorectal Dis* 2006;21:44-51.

39. MacRae HM, McLeod RS. Comparison of hemorrhoidal treatment modalities. A meta-analysis. *Dis Colon Rectum* 1995;38:687-94.
40. Accarpio G, Ballari F, Puglisi R, et al. Outpatient treatment of hemorrhoids with a combined technique: results in 7850 cases. *Tech Coloproctol* 2002;6:195-6.
41. Davis KG, Pelta AE, Armstrong DN. Combined colonoscopy and three-quadrant hemorrhoidal ligation: 500 consecutive cases. *Dis Colon Rectum* 2007;50:1445-9.
42. McCloud JM, Jameson JS, Scott AN. Life-threatening sepsis following treatment for haemorrhoids: a systematic review. *Colorectal Dis* 2006;8:748-55.
43. Adami B, Eckardt VF, Suermann RB, et al. Bacteremia after proctoscopy and hemorrhoidal injection sclerotherapy. *Dis Colon Rectum* 1981;24:373-4.
44. Vindal A, Lal P, Chander J, et al. Rectal perforation after injection sclerotherapy for hemorrhoids: case report. *Indian J Gastroenterol* 2008;27:84-5.
45. Schulte T, Fandrich F, Kahlke V. Life-threatening rectal necrosis after injection sclerotherapy for haemorrhoids. *Int J Colorectal Dis* 2008;23:725-6.
46. Guy RJ, Seow-Choen F. Septic complications after treatment of haemorrhoids. *Br J Surg* 2003;90:147-56.

Prepared by:  
ASGE TECHNOLOGY COMMITTEE  
Uzma D. Siddiqui, MD  
Bradley A. Barth, MD, NASPGHAN Representative  
Subhas Banerjee, MD  
Yasser M. Bhat, MD  
Shailendra S. Chauhan, MD  
Klaus T. Gottlieb, MD, MBA  
Vani Konda, MD  
John T. Maple, DO  
Faris M. Murad, MD  
Patrick Pfau, MD  
Douglas Pleskow, MD  
Jeffrey L. Tokar, MD  
Amy Wang, MD  
Sarah A. Rodriguez, MD, Committee Chair

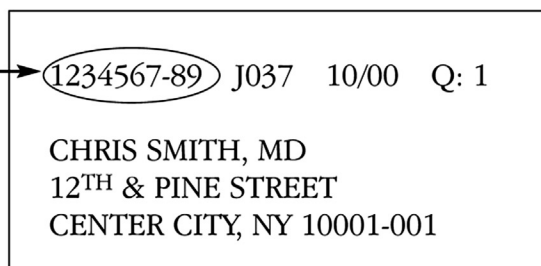
This document is a product of the ASGE Technology Assessment Committee. This document was reviewed and approved by the Governing Board of the American Society for Gastrointestinal Endoscopy.

Access to ***Gastrointestinal Endoscopy Online*** is reserved for all subscribers!

Full-text access to ***Gastrointestinal Endoscopy Online*** is available for all subscribers. ASGE MEMBER SUBSCRIBERS: To activate your individual online subscription, please visit <http://www.asge.org> and follow the instructions. NON-MEMBER SUBSCRIBERS: To activate your individual online subscription, please visit <http://www.giejournal.org> and follow the prompts to activate your *online access*. To activate your account, you will need your subscriber account/membership number, which you can find on your mailing label (*note*: the number of digits in your subscriber account number varies from 6 to 10 digits). See the example below in which the subscriber account number has been circled:

**Sample mailing label**

This is your Nonmember  
subscriber account number



Personal subscriptions to ***Gastrointestinal Endoscopy Online*** are for individual use only and may not be transferred. Use of ***Gastrointestinal Endoscopy Online*** is subject to agreement to the terms and conditions as indicated online.