

Complications of colonoscopy

This is one of a series of position statements discussing the use of GI endoscopy in common clinical situations. The Standards of Practice Committee of the American Society for Gastrointestinal Endoscopy prepared this text. In preparing this document, the authors performed a search of the medical literature by using PubMed. Additional references were obtained from the bibliographies of the identified articles and from recommendations of expert consultants. When limited or no data existed from well-designed prospective trials, emphasis was given to results from large series and reports from recognized experts. Position statements are based on a critical review of the available data and expert consensus at the time the documents are drafted. Further controlled clinical studies may be needed to clarify aspects of this document, which may be revised as necessary to account for changes in technology, new data, or other aspects of clinical practice.

This document is intended to be an educational device to provide information that may assist endoscopists in providing care to patients. This position statement is not a rule and should not be construed as establishing a legal standard of care or as encouraging, advocating, requiring, or discouraging any particular treatment. Clinical decisions in any particular case involve a complex analysis of the patient's condition and available courses of action. Therefore, clinical considerations may lead an endoscopist to take a course of action that varies from this position statement. This document is an update of the 2003 ASGE document entitled "Complications of colonoscopy."¹

Colonoscopy is a commonly performed procedure for the diagnosis and treatment of a wide range of conditions and symptoms and for the screening and surveillance of colorectal neoplasia. Although up to 33% of patients report at least one minor, transient GI symptom after colonoscopy,² serious complications are uncommon. In a 2008 systematic review of 12 studies totaling 57,742 colonoscopies performed for average risk screening, the pooled overall serious adverse event rate was 2.8 per 1000 procedures.³ The risk of some complications may be higher if the colonoscopy is performed for an indication other than screening.⁴ The colorectal cancer miss rate of colonoscopy has been reported to be as high as 6%,⁵ and the miss rate

for adenomas larger than 1 cm is 12% to 17%.⁶⁻⁷ Although missed lesions are considered a poor outcome of colonoscopy, they are not a complication of the procedure per se and will not be discussed further in this document. Complications of bowel preparations are discussed in the American Society for Gastrointestinal Endoscopy Technology Status Evaluation Report for Colonoscopy Preparation.⁸

Over 85% of the serious colonoscopy complications are reported in patients undergoing colonoscopy with polypectomy.³ An analysis of Canadian administrative data, including over 97,000 colonoscopies, found that polypectomy was associated with a 7-fold increase in the risk of bleeding or perforation.⁹ However, complication data are often not stratified by whether or not polypectomy was performed. Therefore, complications of polypectomy are discussed with those of diagnostic colonoscopy. A discussion of the diagnosis and management of all complications of colonoscopy is beyond the scope of this document, although general principles are reviewed.

CARDIOPULMONARY COMPLICATIONS

Cardiovascular and pulmonary complications related to sedation are reviewed in detail in the 2008 American Society for Gastrointestinal Endoscopy Guideline for Sedation and Anesthesia in GI Endoscopy.¹⁰ Intraprocedural cardiopulmonary complications have been variably defined to include events of unclear clinical significance, such as minor fluctuations in oxygen saturation or heart rate, to significant complications including respiratory arrest, cardiac arrhythmias, myocardial infarction, and shock.¹¹ In a study that used the Clinical Outcomes Research Initiative (CORI) database, cardiopulmonary complications occurred in 0.9% of procedures and made up 67% of the unplanned events during or after endoscopic procedures with sedation.¹² Transient hypoxemia occurred in 230 per 100,000 colonoscopies, but prolonged hypoxemia was reported in only 0.78 per 100,000 colonoscopies. Hypotension occurred in 480 per 100,000 colonoscopies. CORI data may underestimate acute complications because of missing data and underreporting. A 2008 systematic review of randomized, controlled trials of patients undergoing colonoscopy and/or EGD reported much higher cardiopulmonary event rates with a weighted rate of 6% to 11% for hypoxemia and 5% to 7% for hypotension, depending on the specific drug regimen used.¹³

In addition to acute complications, colonoscopy is associated with an increased incidence of cardiovascular events in the 30-day postprocedure period. A study of Medicare beneficiaries reported an unadjusted rate of cardiovascular events requiring hospitalization or emergency department visits of 1030 per 100,000 procedures, which was significantly higher compared with matched controls (885/100,000 procedures).⁴ In a prospective study of patients undergoing colonoscopy at CORI sites, the event rate at 30 days was 1.4 per 1000 for angina, myocardial infarction, stroke, or transient ischemic attack.¹⁴

It is known that the risk of cardiopulmonary events associated with colonoscopy is increased with advanced age,⁴ higher American Society of Anesthesiologists Physical Status Classification System scores,¹⁵⁻¹⁶ and the presence of comorbidities.⁴ Appropriate assessment of anesthesia risk prior to colonoscopy may reduce cardiopulmonary complications by ensuring that high-risk patients are co-managed with other specialists (eg, cardiology, anesthesiology). Appropriate monitoring before, during, and after the procedure also may reduce the risk of complications. Unstable patients should have non-emergent colonoscopy delayed as appropriate. In addition, continuing aspirin and other antiplatelet agents in the peri-endoscopic period may reduce the risk of cardiovascular events. The current American Society for Gastrointestinal Endoscopy Guideline for Management of Antithrombotic Agents for Endoscopic Procedures stresses that the risks of bleeding while receiving antithrombotic therapy must be weighed against the risks of a thrombotic event if that therapy is withheld.¹⁷ Although many thrombotic events may be devastating, procedure-related GI bleeding is usually manageable and infrequently associated with significant morbidity or mortality.¹⁷

PERFORATION

Colonic perforation during colonoscopy may result from mechanical forces against the bowel wall, barotrauma, or as a direct result of therapeutic procedures. Early symptoms of perforation include persistent abdominal pain and abdominal distention. Later, patients may develop peritonitis. Plain radiographs of the chest and abdomen may demonstrate free air, although CT scans have been shown to be superior to the upright chest film.¹⁸ Therefore, an abdominal CT scan should be considered for patients with an unrevealing plain film in whom there is a high suspicion of perforation.

The rate of perforation reported in large studies is 0.3% or less and is generally less than 0.1%.² In a large study of screening colonoscopy, perforation was reported in 13 of 84,412 procedures (0.01%).¹⁹ In a case-controlled study of 277,434 Medicaid beneficiaries undergoing colonoscopy, the rate of perforation was 8.2 per 10,000 procedures (0.08%) compared with 0.3 per 10,000 matched controls (0.003%).²⁰ In a study analyzing over 50,000 colonoscopies and using Medicare claims data, the rate of

perforation was 5 to 7 per 10,000 procedures (0.05%-0.07%) and not significantly different for procedures coded as screening without polypectomy, diagnostic without polypectomy, or with polypectomy (regardless of indication).⁴ Finally, in a large study of 116,000 patients undergoing colonoscopy at ambulatory endoscopy centers, there were 37 perforations (0.3%).²¹

Surgical consultation should be obtained in all cases of perforation. Although perforation often requires surgical repair, nonsurgical management may be appropriate in select individuals.²² There is an increasing number of case reports demonstrating the feasibility of using endoscopic clipping devices to repair perforations.²³

There is evidence that performance of colonoscopy by an endoscopist with low procedure volume is associated with increased risk of perforation and bleeding.⁹ Creating a fluid cushion at the base or under large polyps in order to increase the degree of separation of the mucosal layers has been described as a technique to potentially reduce the risk of postpolypectomy perforation.²⁴ It has been suggested that perforation rates greater than 1 in 500 for all colonoscopies or 1 in 1000 for screening colonoscopies should prompt evaluation of whether inappropriate practices are being used.²⁴

HEMORRHAGE

Hemorrhage is most often associated with polypectomy, although it can occur during diagnostic colonoscopy. When associated with polypectomy, hemorrhage may occur immediately or can be delayed for several weeks after the procedure.²⁵ A number of large studies have reported hemorrhage in 1 to 6 per 1000 colonoscopies (0.1%-0.6%).² A study analyzing over 50,000 colonoscopies by using Medicare claims found that the rate of GI hemorrhage was significantly different with or without polypectomy: 2.1 per 1000 procedures coded as screening without polypectomy and 3.7 per 1000 for procedures coded as diagnostic without polypectomy, compared with 8.7 per 1000 for any procedures with polypectomy.⁴

Polyp size has been reported as a risk factor for postpolypectomy bleeding in several studies.²⁶⁻³⁰ Additional risk factors may include the number of polyps removed,³¹⁻³² recent warfarin therapy,^{28,33-34} and polyp histology.^{26,35} Patient comorbidities, such as cardiovascular disease,^{4,26,28} may increase the risk for bleeding but also may be markers for anticoagulation use.³⁴ Multiple, large studies did not find aspirin use associated with postpolypectomy bleeding.^{33-34,36} Another retrospective study found that concomitant use of either aspirin or nonsteroidal anti-inflammatory drugs and clopidogrel was an independent risk factor for bleeding, but aspirin or clopidogrel use alone was not.³¹ Recommendations for the management of antithrombotic therapy in the peri-endoscopic period are discussed in detail in another ASGE document.¹⁷

The site of active bleeding can be identified endoscopically, through red blood cell nuclear scintigraphy, or angiographically.³⁷ Acute postpolypectomy hemorrhage often is immediately apparent and amenable to endoscopic therapy.³⁸⁻³⁹ Nonendoscopic treatment modalities include angiographic embolization and surgery.⁴⁰

Using mini-snare resection without electrocautery instead of hot-biopsy forceps for removal of diminutive polyps may reduce bleeding.⁴¹ The prophylactic use of mechanical methods, such as clips or detachable snares has been reported.⁴²⁻⁴³ A randomized, controlled trial of prophylactic, detachable snare placement prior to polypectomy in 89 patients with large, pedunculated polyps found a significant reduction in bleeding in the detachable snare group (0% vs 12%).⁴³ The placement of endoscopic clips after removal of colon polyps may be beneficial in select patients, although the data are mixed.^{35,44} Injection of epinephrine prior to polypectomy was reported to reduce the incidence of immediate postpolypectomy bleeding, although there was no demonstrated effect on delayed bleeding.^{45,46} It has been suggested that postprocedure bleeding rates of greater than 1% should prompt evaluation of whether inappropriate practices are being used.²⁴

POSTPOLYPECTOMY ELECTROCOAGULATION SYNDROME

Postpolypectomy electrocoagulation syndrome is the result of electrocoagulation injury to the bowel wall that induces a transmural burn and localized peritonitis without evidence of perforation on radiographic studies. The reported incidence of this complication varies widely from 3 per 100,000 (0.003%) to 1 in 1000 (0.1%).²

Typically, patients with postpolypectomy electrocoagulation syndrome present 1 to 5 days after colonoscopy with fever, localized abdominal pain, localized peritoneal signs, and leukocytosis. It is important to recognize this entity because it does not require surgical treatment. Postpolypectomy electrocoagulation syndrome usually is managed with intravenous hydration, broad-spectrum parenteral antibiotics, and nothing by mouth until the symptoms subside.⁴⁷ Successful outpatient management with oral antibiotics has also been reported.⁴⁸

MORTALITY

Death has been rarely reported in relation to colonoscopy, with or without polypectomy. In a 2010 review of colonoscopy complications based on prospective studies and retrospective analyses of large clinical or administrative databases, there were 128 deaths reported among 371,099 colonoscopies, for an unweighted pooled death rate of 0.03%.² All studies reported mortality within 30 days of the colonoscopy, although some reported all-cause mortality whereas others limited their analysis to

colonoscopy-specific mortality. Those reporting all-cause mortality include 116 deaths among 176,834 patients (0.07%).^{4,9,14, 49-52} Among those reporting colonoscopy-specific mortality, there were 19 deaths among 284,097 patients (0.007%).^{9,19,49-56}

INFECTION

Transient bacteremia after colonoscopy, with or with polypectomy, occurs in approximately 4% of procedures, with a range of 0% to 25%.⁵⁷ However, signs or symptoms of infection are rare.⁵⁷ Although individual cases of infection after colonoscopy have been reported, there is no definite causal link with the endoscopic procedure and no proven benefit for antibiotic prophylaxis.⁵⁸ Therefore, current guidelines from the American Heart Association and ASGE recommend against antibiotic prophylaxis for patients undergoing colonoscopy.⁵⁸⁻⁵⁹ A 2008 review⁶⁰ reported that subsequent to the 2003 Multisociety Guideline for Reprocessing of Flexible GI Endoscopes,⁶¹ all reported cases of transmission of infection resulted from defective equipment and/or failure to adhere to reprocessing guidelines. The Multisociety Guideline for Reprocessing of Flexible GI Endoscopes was updated most recently in 2011.⁶²

GAS EXPLOSION

Explosive complications of colonoscopy are rare, but they have serious consequences. A 2007 review reported 9 cases, each resulting in colonic perforation and, in one case, death.⁶³ Gas explosion can occur when combustible levels of hydrogen or methane gas are present in the colonic lumen, oxygen is present, and electrosurgical energy is used (eg, electrocautery or argon plasma coagulation). Suspected risk factors are use of nonabsorbable or incompletely absorbable carbohydrate preparations, such as mannitol, lactulose, or sorbitol,⁶⁴⁻⁶⁵ and incomplete colonic cleansing either because a sigmoidoscopy preparation was used (eg, enemas) or because the result of a colonoscopic purge preparation was inadequate.⁶⁶ Some authors have advocated use of carbon dioxide during colonoscopy as a preventive measure.⁶⁷

ABDOMINAL PAIN OR DISCOMFORT

Less severe, but more common, sequelae of colonoscopy are also important and can impact patient adherence to future colonoscopy.² The most commonly reported minor complications of colonoscopy are bloating (25%)⁶⁸ and abdominal pain and/or discomfort 5% to 11%.⁶⁸⁻⁷⁰ Appropriate techniques, such as avoiding and reducing endoscope looping and minimizing air insufflation should help reduce these symptoms.⁷¹ In addition, randomized trials have demonstrated less postprocedure pain with carbon dioxide compared with standard air insufflation.⁷²⁻⁷⁷ A water immersion technique that avoids air insufflation also

may reduce pain, especially in the setting of minimal or no sedation.⁷⁸⁻⁷⁹

MISCELLANEOUS COMPLICATIONS

Miscellaneous complications of colonoscopy include splenic rupture,⁸⁰⁻⁸¹ acute appendicitis,⁸² diverticulitis,² subcutaneous emphysema,⁸³⁻⁸⁴ and tearing of mesenteric vessels with intraabdominal hemorrhage. Chemical colitis may occur if glutaraldehyde, used during disinfection, has not been adequately rinsed from the endoscope.⁸⁵

COMPLICATIONS ASSOCIATED WITH SPECIFIC COLONOSCOPIC INTERVENTIONS

Colonoscopic tattooing

When a lesion requires marking to aid localization for surgical removal or endoscopic follow-up, a permanent dye is injected to tattoo the colon adjacent to the lesion.⁸⁶ Use of sterile and appropriately diluted solutions has a low rate (0.2%) of complications.⁸⁷

Colonic dilation

Colonic dilation has been used to treat benign strictures at surgical anastomoses and those associated with Crohn's disease.⁸⁸ Two prospective studies with a total of 42 patients with anastomotic strictures not from Crohn's disease reported no complications after dilation.^{89,90} In contrast, a systematic review of 13 studies with 347 patients with Crohn's disease with colonic strictures reported dilation-related complication rates of 0% to 18%, with a pooled complication rate of 2%.⁹¹ Almost all complications were perforations.

Colonic stent placement

Three pooled analyses of 29 to 88 retrospective studies totaling 598 to 1785 patients have yielded similar results for adverse events in the setting of self-expandable metal stents (SEMS) used for malignant obstruction.⁹²⁻⁹⁴ The pooled perforation rates ranged from 3.7% to 4.5%. The pooled stent migration rates ranged from 9.8% to 11.8%, and the stent occlusion rates ranged from 7.3% to 12%. Dilation before or immediately after stent placement is not recommended because of the increased perforation risk.⁸⁸ Since the publication of the pooled analyses, 3 randomized, controlled trials of SEMS compared with surgery were closed early because of high rates of complications in the SEMS arms. These complications included 6 perforations and 5 anastomotic leaks among 47 participants,⁹⁵ 3 perforations among 11 participants,⁹⁶ and 2 perforations among 30 participants (of whom only 14 had a stent placed; ie, 47% technical success rate).⁹⁷ In contrast, a randomized, controlled trial of SEMS as a bridge to surgery (N = 24 in the SEMS arm) reported no stent-related complications.⁹⁸ The difference in estimated complication rates

among the studies may be related to patient population, endoscopist experience, and study design.

Colonic decompression tube placement

The studies examining colonic decompression tube outcomes are limited in size. In 3 series consisting of 139 patients with colonic obstruction, one perforation was reported.⁹⁹⁻¹⁰¹ A series of 50 patients with pseudo-obstruction who underwent 62 colonoscopies with 54 decompression tube placements included one perforation (2% per-patient rate) and an in-hospital mortality rate of 30%, reflecting the underlying comorbidities of patients with pseudo-obstruction.¹⁰²

Percutaneous endoscopic colostomy

Percutaneous endoscopic colostomy has been used to treat slow-transit constipation, recurrent sigmoid volvulus, colonic pseudo-obstruction, and neurogenic bowel in patients refractory to other interventions and considered poor surgical candidates.⁸⁸ Series of percutaneous endoscopic colostomy report major complications in 5% to 12% (mostly peritonitis), with a 3% to 7% rate of procedure-related mortality.¹⁰³⁻¹⁰⁵ Minor complications, such as site infection, buried bumper, and abdominal wall bleeding, exceeded 30% in the only prospective series.¹⁰³ Most reports describe an all-cause in-hospital mortality rate exceeding 25%, reflecting the often frail patients who populate these series.¹⁰³⁻¹⁰⁵

Colonoscopic hemostasis

General descriptions of hemostasis techniques, efficacy, and safety are discussed in a 2009 American Society for Gastrointestinal Endoscopy Technology Status Evaluation Report.³⁹ The use of any hemostatic technique can initially worsen bleeding, but frequently this can be successfully treated by additional application of the same device or use of another hemostatic device. Colonic perforation is a rare complication of endoscopic hemostasis. However, among patients undergoing treatment of angiectasia, particularly in the right colon, perforation has been reported in up to 2.5% of cases.¹⁰⁶ The rare complication of gas explosion during use of argon plasma coagulation is discussed earlier.

Foreign body removal

Colorectal foreign bodies are primarily the result of objects inserted per rectum or swallowed (eg, bones, toothpicks).¹⁰⁷ There also are case reports of migration of extraintestinal foreign bodies into the large intestine (eg, intrauterine contraceptive devices¹⁰⁸ and inguinal hernia mesh¹⁰⁹). A foreign body may cause colonic obstruction. Perforation is a primary concern; the perforation rate likely varies considerably with the type of object (eg, sharp vs blunt) and traumatic versus nontraumatic insertion.¹⁰⁷ In the case of body packing, that is, transporting illegal drugs by swallowing or inserting plastic bags or condoms filled

with the drug, there is the additional risk of rupture of the bag/condom during attempted removal. This can lead to systemic absorption of the drug, overdose, and, potentially, death.¹⁰⁷ Therefore, it is recommended that endoscopic removal of drug-containing packets should not be attempted.¹¹⁰

Prior to any attempted removal of a foreign body, an abdominal plain film to evaluate for free air is recommended.^{107,111} In a series of 83 episodes of a rectal foreign body in 87 patients, 74% were successfully removed nonoperatively.¹¹²

Advanced techniques for colonoscopic tissue removal

Endoscopic mucosal resection (EMR) and endoscopic submucosal dissection (ESD) are advanced techniques used to remove suspected premalignant and early stage malignant lesions.¹¹³ As with standard polypectomy, bleeding and perforation are the most common complications with EMR and ESD, but they occur more frequently with these advanced techniques. The reported complication rates vary. Lesion size, location, and histology and operator experience may all contribute to this variability.¹¹⁴⁻¹¹⁶

The intraprocedural bleeding rate is over 10% in several large series, with delayed bleeding reported in 1.5% to 14% of cases.^{113,114} Bleeding complications are usually endoscopically manageable, although the need for transfusions has been reported.¹¹⁷ Perforation complicates approximately 5% to 10% of colonic ESD resections^{114-115,117} and, less commonly, complicates EMR resections (0%-5%).¹¹⁸ The majority of perforations are recognized at the time of the procedure and are usually successfully managed with endoscopic clip closure.^{114-115,117}

CONCLUSION

Complications are inherent in the performance of colonoscopy. As endoscopy assumes a more therapeutic role in the management of GI disorders, the potential for complications will likely increase. Knowledge of potential endoscopic complications, their expected frequency, and the risk factors associated with their occurrence may help to minimize the incidence of complications. Endoscopists are expected to carefully select patients for the appropriate intervention, be familiar with the planned procedure and available technology, and be prepared to manage any adverse events that may arise. Once a complication occurs, early recognition and prompt intervention will minimize the morbidity and mortality associated with that complication. Review of complications as part of a continuing quality improvement process may serve to educate endoscopists, help to reduce the risk of future complications, and improve the overall quality of endoscopy.¹¹⁹

DISCLOSURE

D. Fisher is a consultant for Epigenomics. P. Malpas is a consultant for Olympus America. J. Dominitz is a consultant for Epigenomics and Salix Pharmaceuticals. B. Cash is a consultant for Salix Pharmaceuticals, J. Evans is a consultant for Cook Medical. G. Decker is a consultant for Facet Biotechnology. No other financial relationships relevant to this publication were disclosed.

Abbreviations: CORI, Clinical Outcomes Research Initiative; ESD, endoscopic submucosal dissection; SEMS, self-expandable metal stent.

REFERENCES

1. Dominitz JA, Eisen GM, Baron TH, et al. Complications of colonoscopy. *Gastrointest Endosc* 2003;57:441-5.
2. Ko CW, Dominitz JA. Complications of colonoscopy: magnitude and management. *Gastrointest Endosc Clin N Am* 2010;20:659-71.
3. Whitlock EP, Lin JS, Liles E, et al. Screening for colorectal cancer: a targeted, updated systematic review for the U.S. Preventive Services Task Force.[see comment][summary for patients in *Ann Intern Med* 2008;149:1-44; PMID: 18838719 Epub 2008 Oct 6]. *Ann Int Med* 2008;149:638-58.
4. Warren JL, Klabunde CN, Mariotto AB, et al. Adverse events after outpatient colonoscopy in the Medicare population. *Ann Intern Med* 2009;150:849-57, W152.
5. Bressler B, Paszat LF, Chen Z, et al. Rates of new or missed colorectal cancers after colonoscopy and their risk factors: a population-based analysis. *Gastroenterology* 2007;132:96-102.
6. Pickhardt PJ, Nugent PA, Mysliwiec PA, et al. Location of adenomas missed by optical colonoscopy. *Ann Intern Med* 2004;141:352-9.
7. Van Gelder RE, Nio CY, Florie J, et al. Computed tomographic colonography compared with colonoscopy in patients at increased risk for colorectal cancer. *Gastroenterology* 2004;127:41-8.
8. Mamula P, Adler DG, Conway JD, et al. Colonoscopy preparation. *Gastrointest Endosc* 2009;69:1201-9.
9. Rabeneck L, Paszat LF, Hilsden RJ, et al. Bleeding and perforation after outpatient colonoscopy and their risk factors in usual clinical practice. *Gastroenterology* 2008;135:1899-1906, 1906 e1891.
10. Lichtenstein DR, Jagannath S, Baron TH, et al. Sedation and anesthesia in GI endoscopy. *Gastrointest Endosc* 2008;68:815-26.
11. Cotton PB, Eisen GM, Aabakken L, et al. A lexicon for endoscopic adverse events: report of an ASGE workshop. *Gastrointest Endosc* 2010;71:446-54.
12. Sharma VK, Nguyen CC, Crowell MD, et al. A national study of cardiopulmonary unplanned events after GI endoscopy. *Gastrointest Endosc* 2007;66:27-34.
13. McQuaid KR, Laine L. A systematic review and meta-analysis of randomized, controlled trials of moderate sedation for routine endoscopic procedures. *Gastrointest Endosc* 2008;67:910-23.
14. Ko CW, Riffle S, Michaels L, et al. Serious complications within 30 days of screening and surveillance colonoscopy are uncommon. *Clin Gastroenterol Hepatol* 2010;8:166-73.
15. Baudet JS, Diaz-Bethencourt D, Aviles J, et al. Minor adverse events of colonoscopy on ambulatory patients: the impact of moderate sedation. *Eur J Gastroenterol Hepatol* 2009;21:656-61.
16. Vargo JJ, Holub JL, Faigel DO, et al. Risk factors for cardiopulmonary events during propofol-mediated upper endoscopy and colonoscopy. *Aliment Pharmacol Ther* 2006;24:955-63.
17. Anderson MA, Ben-Menachem T, Gan SI, et al. Management of anti-thrombotic agents for endoscopic procedures. *Gastrointest Endosc* 2009;70:1060-70.
18. Stapakis JC, Thickman D. Diagnosis of pneumoperitoneum: abdominal CT vs. upright chest film. *J Comput Assist Tomogr* 1992;16:713-6.

19. Sieg A, Hachmoeller-Eisenbach U, Eisenbach T. Prospective evaluation of complications in outpatient GI endoscopy: a survey among German gastroenterologists. *Gastrointest Endosc* 2001;53:620-7.
20. Arora G, Mannalithara A, Singh G, et al. Risk of perforation from a colonoscopy in adults: a large population-based study. *Gastrointest Endosc* 2009;69(3, pt 2):654-64.
21. Korman LY, Overholt BF, Box T, et al. Perforation during colonoscopy in endoscopic ambulatory surgical centers. *Gastrointest Endosc* 2003;58:554-7.
22. Orsoni P, Berdah S, Verrier C, et al. Colonic perforation due to colonoscopy: a retrospective study of 48 cases. *Endoscopy* 1997;29:160-4.
23. Trecca A, Gaj F, Gagliardi G. Our experience with endoscopic repair of large colonoscopic perforations and review of the literature. *Tech Coloproctol* 2008;12:315-21; discussion 322.
24. Rex DK, Petrini JL, Baron TH, et al. Quality indicators for colonoscopy. *Gastrointest Endosc* 2006;63(suppl 4):S16-28.
25. Singaram C, Torbey CF, Jacoby RF. Delayed postpolypectomy bleeding. *Am J Gastroenterol* 1995;90:146-7.
26. Consolo P, Luigiano C, Strangio G, et al. Efficacy, risk factors and complications of endoscopic polypectomy: ten year experience at a single center. *World J Gastroenterol* 21 2008;14:2364-9.
27. Dafnis G, Ekbohm A, Pahlman L, et al. Complications of diagnostic and therapeutic colonoscopy within a defined population in Sweden. *Gastrointest Endosc* 2001;54:302-9.
28. Kim HS, Kim TI, Kim WH, et al. Risk factors for immediate postpolypectomy bleeding of the colon: a multicenter study. *Am J Gastroenterol* 2006;101:1333-41.
29. Shiffman ML, Farrel MT, Yee YS. Risk of bleeding after endoscopic biopsy or polypectomy in patients taking aspirin or other NSAIDs. *Gastrointest Endosc* 1994;40:458-62.
30. Watabe H, Yamaji Y, Okamoto M, et al. Risk assessment for delayed hemorrhagic complication of colonic polypectomy: polyp-related factors and patient-related factors. *Gastrointest Endosc* 2006;64:73-78.
31. Singh M, Mehta N, Murthy UK, et al. Postpolypectomy bleeding in patients undergoing colonoscopy on uninterrupted clopidogrel therapy. *Gastrointest Endosc* 2010;71:998-1005.
32. Witt DM, Delate T, McCool KH, et al. Incidence and predictors of bleeding or thrombosis after polypectomy in patients receiving and not receiving anticoagulation therapy. *J Thromb Haemost* 2009;7:1982-89.
33. Hui AJ, Wong RM, Ching JY, et al. Risk of colonoscopic polypectomy bleeding with anticoagulants and antiplatelet agents: analysis of 1657 cases. *Gastrointest Endosc* 2004;59:44-8.
34. Sawhney MS, Salfiti N, Nelson DB, et al. Risk factors for severe delayed postpolypectomy bleeding. *Endoscopy* 2008;40:115-9.
35. Luigiano C, Ferrara F, Ghersi S, et al. Endoclip-assisted resection of large pedunculated colorectal polyps: technical aspects and outcome. *Dig Dis Sci* 2010;55:1726-31.
36. Yousfi M, Gostout CJ, Baron TH, et al. Postpolypectomy lower gastrointestinal bleeding: potential role of aspirin. *Am J Gastroenterol* 2004;99:1785-9.
37. Gibbs DH, Opelka FG, Beck DE, et al. Postpolypectomy colonic hemorrhage. *Dis Colon Rectum* 1996;39:806-10.
38. Carpenter S, Petersen BT, Chuttani R, et al. Polypectomy devices. *Gastrointest Endosc* 2007;65:741-9.
39. Conway JD, Adler DG, Diehl DL, et al. Endoscopic hemostatic devices. *Gastrointest Endosc* 2009;69:987-96.
40. Sorbi D, Norton I, Conio M, et al. Postpolypectomy lower GI bleeding: descriptive analysis. *Gastrointest Endosc* 2000;51:690-6.
41. Tappero G, Gaia E, De Giuli P, et al. Cold snare excision of small colorectal polyps. *Gastrointest Endosc* 1992;38:310-3.
42. Iida Y, Miura S, Munemoto Y, et al. Endoscopic resection of large colorectal polyps using a clipping method. *Dis Colon Rectum* 1994;37:179-80.
43. Iishi H, Tatsuta M, Narahara H, et al. Endoscopic resection of large pedunculated colorectal polyps using a detachable snare. *Gastrointest Endosc* 1996;44:594-7.
44. Shioji K, Suzuki Y, Kobayashi M, et al. Prophylactic clip application does not decrease delayed bleeding after colonoscopic polypectomy. *Gastrointest Endosc* 2003;57:691-4.
45. Hsieh YH, Lin HJ, Tseng GY, et al. Is submucosal epinephrine injection necessary before polypectomy? A prospective, comparative study. *Hepatogastroenterology* 2001;48:1379-82.
46. Di Giorgio P, De Luca L, Calcagno G, et al. Detachable snare versus epinephrine injection in the prevention of postpolypectomy bleeding: a randomized and controlled study. *Endoscopy* 2004;36:860-3.
47. Nivatvongs S. Complications in colonoscopic polypectomy. an experience with 1,555 polypectomies. *Dis Colon Rectum* 1986;29:825-30.
48. Wayne JD, Lewis BS, Yessayan S. Colonoscopy: a prospective report of complications. *J Clin Gastroenterol* 1992;15:347-51.
49. Levin TR, Zhao W, Conell C, et al. Complications of colonoscopy in an integrated health care delivery system. *Ann Intern Med* 2006;145:880-6.
50. Imperiale TF, Wagner DR, Lin CY, et al. Risk of advanced proximal neoplasms in asymptomatic adults according to the distal colorectal findings. *N Engl J Med* 2000;343:169-74.
51. Nelson DB, McQuaid KR, Bond JH, et al. Procedural success and complications of large-scale screening colonoscopy. *Gastrointest Endosc* 2002;55:307-14.
52. Rathgeber SW, Wick TM. Colonoscopy completion and complication rates in a community gastroenterology practice. *Gastrointest Endosc* 2006;64:556-62.
53. Viiala CH, Zimmerman M, Cullen DJ, et al. Complication rates of colonoscopy in an Australian teaching hospital environment. *Intern Med J* 2003;33:355-59.
54. Gatto NM, Frucht H, Sundararajan V, et al. Risk of perforation after colonoscopy and sigmoidoscopy: a population-based study. *J Natl Cancer Inst* 2003;95:230-6.
55. Anderson ML, Pasha TM, Leighton JA. Endoscopic perforation of the colon: lessons from a 10-year study. *Am J Gastroenterol* 2000;95:3418-22.
56. Tran DQ, Rosen L, Kim R, et al. Actual colonoscopy: What are the risks of perforation? *Am Surg* 2001;67:845-7; discussion 847-8.
57. Nelson DB. Infectious disease complications of GI endoscopy: part II, exogenous infections. *Gastrointest Endosc* 2003;57:695-711.
58. Banerjee S, Shen B, Baron TH, et al. Antibiotic prophylaxis for GI endoscopy. *Gastrointest Endosc* 2008;67:791-8.
59. Wilson W, Taubert KA, Gewitz M, et al. Prevention of infective endocarditis: guidelines from the American Heart Association: a guideline from the American Heart Association Rheumatic Fever, Endocarditis, and Kawasaki Disease Committee, Council on Cardiovascular Disease in the Young, and the Council on Clinical Cardiology, Council on Cardiovascular Surgery and Anesthesia, and the Quality of Care and Outcomes Research Interdisciplinary Working Group. *Circulation* 2007;116:1736-54.
60. Banerjee S, Shen B, Nelson DB, et al. Infection control during GI endoscopy. *Gastrointest Endosc* 2008;67:781-90.
61. Multi-society guideline for reprocessing flexible gastrointestinal endoscopes. *Gastrointest Endosc* 2003;58:1-8.
62. Petersen BT, Chennat J, Cohen J, et al. Multisociety guideline on reprocessing flexible gastrointestinal endoscopes: 2011. *Gastrointest Endosc* 2011;73:1075-84.
63. Ladas SD, Karamanolis G, Ben-Soussan E. Colonic gas explosion during therapeutic colonoscopy with electrocautery. *World J Gastroenterol* 2007;13:5295-8.
64. Avgerinos A, Kalantzis N, Rekoumis G, et al. Bowel preparation and the risk of explosion during colonoscopic polypectomy. *Gut* 1984;25:361-4.
65. La Brooy SJ, Avgerinos A, Fendick CL, et al. Potentially explosive colonic concentrations of hydrogen after bowel preparation with mannitol. *Lancet* 1981;1:634-6.
66. Monahan DW, Peluso FE, Goldner F. Combustible colonic gas levels during flexible sigmoidoscopy and colonoscopy. *Gastrointest Endosc* 1992;38:40-3.

67. Hofstad B. Explosion in rectum [in Norwegian with English abstract]. *Tidsskr Nor Laegeforen* 2007;127:1789-90.
68. Ko CW, Riffle S, Shapiro JA, et al. Incidence of minor complications and time lost from normal activities after screening or surveillance colonoscopy. *Gastrointest Endosc* 2007;65:648-56.
69. Bini EJ, Firoozi B, Choung RJ, et al. Systematic evaluation of complications related to endoscopy in a training setting: a prospective 30-day outcomes study. *Gastrointest Endosc* 2003;57:8-16.
70. Zubarik R, Fleischer DE, Mastrogiorgio C, et al. Prospective analysis of complications 30 days after outpatient colonoscopy. *Gastrointest Endosc* 1999;50:322-28.
71. Waye JD. The most important maneuver during colonoscopy. *Am J Gastroenterol* 2004;99:2086-7.
72. Bretthauer M, Thiis-Evensen E, Huppertz-Hauss G, et al. NORCCAP (Norwegian colorectal cancer prevention): a randomised trial to assess the safety and efficacy of carbon dioxide versus air insufflation in colonoscopy. *Gut* 2002;50:604-7.
73. Church J, Delaney C. Randomized, controlled trial of carbon dioxide insufflation during colonoscopy. *Dis Colon Rectum* 2003;46:322-6.
74. Riss S, Akan B, Mikola B, et al. CO₂ insufflation during colonoscopy decreases post-interventional pain in deeply sedated patients: a randomized controlled trial. *Wien Klin Wochenschr* 2009;121:464-8.
75. Stevenson GW, Wilson JA, Wilkinson J, et al. Pain following colonoscopy: elimination with carbon dioxide. *Gastrointest Endosc* 1992;38:564-7.
76. Sumanac K, Zealley I, Fox BM, et al. Minimizing postcolonoscopy abdominal pain by using CO₂ insufflation: a prospective, randomized, double blind, controlled trial evaluating a new commercially available CO₂ delivery system. *Gastrointest Endosc* 2002;56:190-4.
77. Wong JC, Yau KK, Cheung HY, et al. Towards painless colonoscopy: a randomized controlled trial on carbon dioxide-insufflating colonoscopy. *ANZ J Surg* 2008;78:871-4.
78. Leung CW, Kaltenbach T, Soetikno R, et al. Water immersion versus standard colonoscopy insertion technique: randomized trial shows promise for minimal sedation. *Endoscopy* 2010;42:557-63.
79. Leung JW, Mann SK, Siao-Salera R, et al. A randomized, controlled comparison of warm water infusion in lieu of air insufflation versus air insufflation for aiding colonoscopy insertion in sedated patients undergoing colorectal cancer screening and surveillance. *Gastrointest Endosc* 2009;70:505-10.
80. Kamath AS, Iqbal CW, Sarr MG, et al. Colonoscopic splenic injuries: incidence and management. *J Gastrointest Surg* 2009;13:2136-40.
81. Michetti CP, Smeltzer E, Fakhry SM. Splenic injury due to colonoscopy: analysis of the world literature, a new case report, and recommendations for management. *Am Surg* 2010;76:1198-1204.
82. Hirata K, Noguchi J, Yoshikawa I, et al. Acute appendicitis immediately after colonoscopy. *Am J Gastroenterol* 1996;91:2239-40.
83. Bakker J, van Kersen F, Bellaar Spruyt J. Pneumopericardium and pneumomediastinum after polypectomy. *Endoscopy* 1991;23:46-7.
84. Humphreys F, Hewetson KA, Dellipiani AW. Massive subcutaneous emphysema following colonoscopy. *Endoscopy* 1984;16:160-1.
85. Caprilli R, Viscido A, Frieri G, et al. Acute colitis following colonoscopy. *Endoscopy* 1998;30:428-31.
86. Kethu SR, Banerjee S, Desilets D, et al. Endoscopic tattooing. *Gastrointest Endosc* 2010;72:681-5.
87. Nizam R, Siddiqi N, Landas SK, et al. Colonic tattooing with India ink: benefits, risks, and alternatives. *Am J Gastroenterol* 1996;91:1804-8.
88. Harrison ME, Anderson MA, Appalaneni V, et al. The role of endoscopy in the management of patients with known and suspected colonic obstruction and pseudo-obstruction. *Gastrointest Endosc* 2010;71:669-79.
89. Di Giorgio P, De Luca L, Rivellini G, et al. Endoscopic dilation of benign colorectal anastomotic stricture after low anterior resection: a prospective comparison study of two balloon types. *Gastrointest Endosc* 2004;60:347-50.
90. Ambrosetti P, Francis K, De Peyer R, et al. Colorectal anastomotic stenosis after elective laparoscopic sigmoidectomy for diverticular disease: a prospective evaluation of 68 patients. *Dis Colon Rectum* 2008;51:1345-9.
91. Hassan C, Zullo A, De Francesco V, et al. Systematic review: endoscopic dilatation in Crohn's disease. *Aliment Pharmacol Ther* 2007;26:1457-64.
92. Khot UP, Lang AW, Murali K, et al. Systematic review of the efficacy and safety of colorectal stents. *Br J Surg* 2002;89:1096-1102.
93. Sebastian S, Johnston S, Geoghegan T, et al. Pooled analysis of the efficacy and safety of self-expanding metal stenting in malignant colorectal obstruction. *Am J Gastroenterol* 2004;99:2051-7.
94. Watt AM, Faragher IG, Griffin TT, et al. Self-expanding metallic stents for relieving malignant colorectal obstruction: a systematic review. *Ann Surg* 2007;246:24-30.
95. van Hooft JE, Bemelman WA, Oldenburg B, et al. Colonic stenting versus emergency surgery for acute left-sided malignant colonic obstruction: a multicentre randomised trial. *Lancet Oncol* 2011;12:344-52.
96. van Hooft JE, Fockens P, Marinelli AW, et al. Early closure of a multicenter randomized clinical trial of endoscopic stenting versus surgery for stage IV left-sided colorectal cancer. *Endoscopy* 2008;40:184-91.
97. Pirllet IA, Slim K, Kwiatkowski F, et al. Emergency preoperative stenting versus surgery for acute left-sided malignant colonic obstruction: a multicenter randomized controlled trial. *Surg Endosc* 2011;25:1814-21.
98. Cheung HY, Ng KH, Leung AL, et al. Laparoscopic sphincter-preserving total mesorectal excision: 10-year report. *Colorectal Dis* 2011;13:627-31.
99. Fischer A, Schrag HJ, Goos M, et al. Transanal endoscopic tube decompression of acute colonic obstruction: experience with 51 cases. *Surg Endosc* 2008;22:683-8.
100. Horiuchi A, Nakayama Y, Tanaka N, et al. Acute colorectal obstruction treated by means of transanal drainage tube: effectiveness before surgery and stenting. *Am J Gastroenterol* 2005;100:2765-70.
101. Tanaka T, Furukawa A, Murata K, et al. Endoscopic transanal decompression with a drainage tube for acute colonic obstruction: clinical aspects of preoperative treatment. *Dis Colon Rectum* 2001;44:418-22.
102. Geller A, Petersen BT, Gostout CJ. Endoscopic decompression for acute colonic pseudo-obstruction. *Gastrointest Endosc* 1996;44:144-50.
103. Baraza W, Brown S, McAlindon M, et al. Prospective analysis of percutaneous endoscopic colostomy at a tertiary referral centre. *Br J Surg* 2007;94:1415-20.
104. Bertolini D, De Saussure P, Chilcott M, et al. Severe delayed complication after percutaneous endoscopic colostomy for chronic intestinal pseudo-obstruction: a case report and review of the literature. *World J Gastroenterol* 2007;13:2255-7.
105. Cowlam S, Watson C, Elltringham M, et al. Percutaneous endoscopic colostomy of the left side of the colon. *Gastrointest Endosc* 2007;65:1007-14.
106. Foutch PG. Angiodysplasia of the gastrointestinal tract. *Am J Gastroenterol* 1993;88:807-18.
107. Goldberg JE, Steele SR. Rectal foreign bodies. *Surg Clin North Am* 2010;90:173-84: Table of contents.
108. Assarian A, Raja MA. Colonoscopic retrieval of a lost intrauterine contraceptive device: a case report and review of articles. *Eur J Contracept Reprod Health Care* 2005;10:261-5.
109. Celik A, Kutun S, Kockar C, et al. Colonoscopic removal of inguinal hernia mesh: report of a case and literature review. *J Laparoendosc Adv Surg Tech A* 2005;15:408-10.
110. ASGE Standards of Practice Committee; Ikenberry SO, Jue T, Anderson MA, et al. Management of ingested foreign bodies and food impactions. *Gastrointest Endosc* 2011;73:1085-91.
111. Koornstra JJ, Weersma RK. Management of rectal foreign bodies: description of a new technique and clinical practice guidelines. *World J Gastroenterol* 2008;14:4403-6.
112. Lake JP, Essani R, Petrone P, et al. Management of retained colorectal foreign bodies: predictors of operative intervention. *Dis Colon Rectum*. 2004;47:1694-8.
113. Kantsevov SV, Adler DG, Conway JD, et al. Endoscopic mucosal resection and endoscopic submucosal dissection. *Gastrointest Endosc* 2008;68:11-8.

114. Saito Y, Uraoka T, Yamaguchi Y, et al. A prospective, multicenter study of 1111 colorectal endoscopic submucosal dissections (with video). *Gastrointest Endosc* 2010;72:1217-25.

115. Tanaka S, Oka S, Kaneko I, et al. Endoscopic submucosal dissection for colorectal neoplasia: possibility of standardization. *Gastrointest Endosc* 2007;66:100-7.

116. Toyonaga T, Man-i M, Fujita T, et al. Retrospective study of technical aspects and complications of endoscopic submucosal dissection for laterally spreading tumors of the colorectum. *Endoscopy* 2010;42:714-22.

117. Niimi K, Fujishiro M, Kodashima S, et al. Long-term outcomes of endoscopic submucosal dissection for colorectal epithelial neoplasms. *Endoscopy* 2010;42:723-9.

118. Repici A, Pellicano R, Strangio G, et al. Endoscopic mucosal resection for early colorectal neoplasia: pathologic basis, procedures, and outcomes. *Dis Colon Rectum* 2009;52:1502-15.

119. Faigel DO, Pike IM, Baron TH, et al. Quality indicators for gastrointestinal endoscopic procedures: an introduction. *Gastrointest Endosc* 2006;63(suppl 4):S3-9.

- Deborah A. Fisher, MD, MHS, FASGE
John T. Maple, DO
Tamir Ben-Menachem, MD
Brooks D. Cash, MD
G. Anton Decker, MD
Dayna S. Early, MD, FASGE
John A. Evans, MD
Robert D. Fanelli, MD, SAGES Representative
Norio Fukami, MD
Joo Ha Hwang, MD, PhD, FASGE
Rajeev Jain, MD
Terry L. Jue, MD
Khalid M. Khan, MD, NASPGHN Representative
Phyllis M. Malpas, MA, RN, CGRN, SGNA Representative
Ravi N. Sharaf, MD
Amandeep K. Shergill, MD
Jason A. Dominitz, MD, MHS, FASGE (Chair)

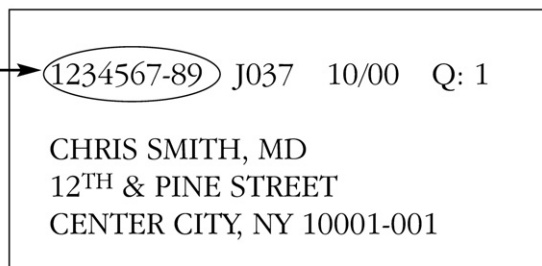
Prepared by:
ASGE STANDARDS OF PRACTICE COMMITTEE

Access to ***Gastrointestinal Endoscopy Online*** is reserved for all subscribers!

Full-text access to ***Gastrointestinal Endoscopy Online*** is available for all subscribers. ASGE MEMBER SUBSCRIBERS: To activate your individual online subscription, please visit <http://www.asge.org> and follow the instructions. NON-MEMBER SUBSCRIBERS: To activate your individual online subscription, please visit <http://www.giejournal.org> and follow the prompts to activate your *online access*. To activate your account, you will need your subscriber account/membership number, which you can find on your mailing label (*note*: the number of digits in your subscriber account number varies from 6 to 10 digits). See the example below in which the subscriber account number has been circled:

Sample mailing label

This is your Nonmember subscriber account number →



Personal subscriptions to ***Gastrointestinal Endoscopy Online*** are for individual use only and may not be transferred. Use of ***Gastrointestinal Endoscopy Online*** is subject to agreement to the terms and conditions as indicated online.