

The role of endoscopy in the evaluation and management of patients with solid pancreatic neoplasia

Prepared by: ASGE STANDARDS OF PRACTICE COMMITTEE

Mohamad A. Eloubeidi, MD, MHS, FASGE, G. Anton Decker, MBBCh, MRCP, MHA, Vinay Chandrasekhara, MD, Krishnavel V. Chathadi, MD, Dayna S. Early, MD, FASGE, John A. Evans, MD, Robert D. Fanelli, MD, MHA, FACS, FASGE, Deborah A. Fisher, MD, MHS, FASGE, Kimberly Foley, RN, BSN, CGRN, Joo Ha Hwang, MD, PhD, FASGE, Terry L. Jue, MD, Jenifer R. Lightdale, MD, MPH, FASGE, Shabana F. Pasha, MD, John R. Saltzman, MD, FASGE, Ravi Sharaf, MD, Amandeep K. Shergill, MD, Brooks D. Cash, MD, FASGE, Previous Committee Chair, John M. DeWitt, MD, FASGE, Chair

This document was reviewed and approved by the Governing Board of the American Society for Gastrointestinal Endoscopy.

This is one of a series of statements discussing the use of GI endoscopy in common clinical situations. The Standards of Practice Committee of the American Society for Gastrointestinal Endoscopy (ASGE) prepared this document that updates a previously issued consensus statement and a technology status evaluation report on this topic.¹ In preparing this guideline, a search of the medical literature was performed by using PubMed between January 1975 and May 2015, with the use of the search terms “pancreatic AND malignancy,” “endoscopy,” “EUS,” and “ERCP.” Additional references were obtained from the bibliographies of the identified articles and from recommendations of expert consultants. When limited or no data existed from well-designed prospective trials, emphasis is given to results from large series and reports from recognized experts. Recommendations for appropriate use of endoscopy are based on a critical review of the available data and expert consensus at the time the documents are drafted. Further controlled clinical studies may be needed to clarify aspects of recommendations contained in this document. This document may be revised as necessary to account for changes in technology, new data, or other aspects of clinical practice. The recommendations were based on reviewed studies and were graded on the strength of the supporting evidence (Table 1).² The strength of individual recommendations is based both on the aggregate evidence quality and an assessment of the anticipated benefits and harms. Weaker recommendations are indicated by phrases such as “we suggest,” whereas stronger recommendations are typically stated as “we recommend.”

This guideline is intended to be an educational device to provide information that may assist endoscopists in providing care to patients. It is not a rule and should not be construed as establishing a legal standard of care or as encouraging, advocating, requiring, or discouraging any particular treatment. Clinical decisions in any particular case involve a complex analysis of the patient's condition and available courses of action. Therefore, clinical considerations may lead an endoscopist to take a course of action that varies from these recommendations and suggestions.

This document reviews the approach to the evaluation and treatment of the patient with suspected solid pancreatic neoplasia. Table 2 outlines the types of neoplasia discussed in this guideline. A discussion of the role of endoscopy for cystic lesions of the pancreas can be found in another ASGE document.³ Solid lesions of the pancreas can be classified as primary or metastatic, benign or malignant, and arising from the exocrine or endocrine pancreas. The most common and potentially serious solid lesion of the pancreas, pancreatic adenocarcinoma, arises from the exocrine pancreas. An algorithm of the recommended approach to pancreatic adenocarcinoma diagnosis and staging is presented in Figure 1.

PRESENTATION AND CLINICAL EVALUATION

Patients with suspected solid pancreatic neoplasia may present with obstructive jaundice, abdominal pain, anorexia, weight loss, acute pancreatitis, new onset or poorly controlled diabetes, or steatorrhea. The physical examination can include findings such as jaundice, muscle wasting, pertinent skin lesions, palpable adenopathy, hepatomegaly, or masses. Occasionally these lesions will be

TABLE 1. GRADE system for the quality of evidence for guidelines

Quality of evidence	Definition	Symbol
High quality	Further research is very unlikely to change our confidence in the estimate of effect.	⊕⊕⊕⊕
Moderate quality	Further research is likely to have an important impact on our confidence in the estimate of effect and may change the estimate.	⊕⊕⊕○
Low quality	Further research is very likely to have an important impact on our confidence in the estimate of effect and is likely to change the estimate.	⊕⊕○○
Very low quality	Any estimate of effect is very uncertain.	⊕○○○

GRADE, Grading of recommendations assessment, development and evaluation. Adapted from Guyatt et al.²

identified coincidentally on surveillance abdominal imaging tests or during evaluation of unrelated abdominal pain. Elevations in routine or diagnostic liver enzyme testing, especially increased levels of bilirubin and alkaline phosphatase, may lead to a diagnosis of cholestasis due to biliary obstruction localized to the head of the pancreas. Conversely, patients with pancreatic malignancy in the body and tail typically present with more advanced-stage disease and normal liver biochemistry results because of the absence of biliary obstruction. The utility of serum markers such as CA 19-9 in patients with suspected pancreatic neoplasia is controversial. CA19-9 levels are elevated in the peripheral blood of the majority of patients with pancreatic cancer, but this finding does not achieve the performance required for either early detection or diagnosis, because of the potential for both false positive and false negative results.⁴ However, despite its shortcomings, CA 19-9 is the only U.S. Food and Drug Administration approved biomarker recommended for use in the routine management of pancreatic ductal adenocarcinoma. It has been used for prognosis and as a marker of disease burden (ie, recurrence or disease progression).⁵ Suspicion of pancreatic neoplasia should prompt additional investigation with chest and abdominal imaging studies to assist in diagnosis, staging, and therapeutic planning. The staging guidelines included here are from the American Joint Committee on Cancer 7th edition TNM staging system (Table 3).⁶

ADENOCARCINOMA OF THE PANCREAS

The American Cancer Society estimates that 48,960 cases of pancreatic cancer developed in 2015 in the United States, and the majority of patients (40,560) will die from the disease.⁷ Most patients with adenocarcinoma of the pancreatic head present with obstructive jaundice.⁸

TABLE 2. Pancreatic neoplasia

Primary
Pancreatic neoplasia
Malignant
Exocrine
Pancreatic adenocarcinoma (solid and/or cystic)
Acinar cell
Endocrine
Neuroendocrine tumors
Benign
Exocrine
Solid pseudopapillary tumor
Cystic neoplasms of the pancreas
Endocrine
Neuroendocrine tumors
Metastatic
Unclassified
Lymphoma

Symptoms generally do not occur until advanced disease is present among patients with pancreatic adenocarcinoma involving the body or tail, hence these patients are less likely to have resectable tumors. The endoscopic evaluation of solid pancreatic tumors is directed toward detection, staging, and obtaining a correct tissue diagnosis in cases that are not going directly to surgery. Correct pathologic diagnosis in rare cases of lymphoma or autoimmune pancreatitis mimicking pancreatic cancer might preclude surgery in these patients. Cross-sectional radiologic imaging typically precedes endoscopy in these patients and aids in tumor detection, localization, and determination of resectability.

Radiologic modalities

Transabdominal US. Transabdominal US (TUS) may suggest biliary obstruction by demonstrating biliary ductal dilation. It also may identify the presence of obvious liver metastases. TUS is operator dependent and has a poor sensitivity for detecting small neoplasms of the pancreatic head.⁹ However, recent advances such as color-power Doppler US, contrast-enhanced US, harmonic imaging, and 3-dimensional (3-D) US may improve the utility of this modality in the staging of pancreatic cancer.¹⁰ Contrast-enhanced US is useful in evaluating the real-time vascularity of various pancreatic masses, which may aid in the differential diagnosis of pancreatic mass lesions.¹¹ Nonetheless, more information regarding staging and extent of disease, and possible nodal or vascular involvement, can be obtained with other imaging modalities.

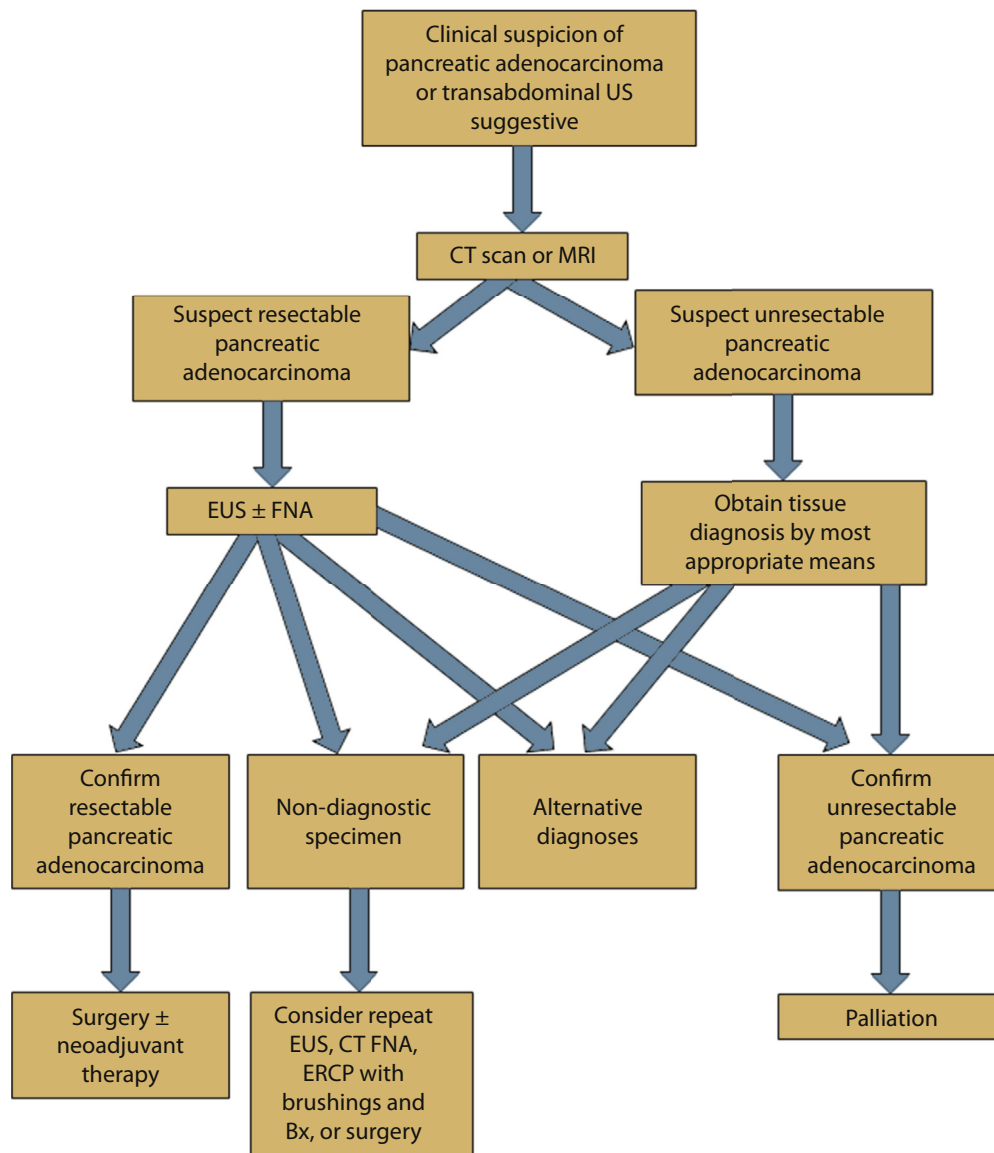


Figure 1. Algorithm for evaluation and management of patients with suspected pancreatic adenocarcinoma.

CT and magnetic resonance imaging. CT is the most widely available modality for the noninvasive assessment of tumor resectability and detection of liver metastases, information that allows further planning of tissue confirmation and palliative care. CT imaging has significantly improved with the introduction of multiple-detector CT, which allows high-resolution 3-D imaging and multiplanar image reconstruction. Faster injection of iodinated contrast medium and precisely timed post-injection image acquisition are techniques that have improved the sensitivity of CT for detecting pancreatic adenocarcinoma.¹²

CT is insensitive for the detection of pancreatic lesions <2 cm in size.¹²⁻¹⁴ It is very sensitive for identification of larger tumors and can accurately stage and assess resectability by detection of tumor extension, liver metastases, and invasion of vascular structures.¹⁵⁻¹⁸ If CT findings

highly suggest a resectable pancreatic carcinoma, and the patient is deemed to be an operative candidate, it may be reasonable to refer the patient directly for surgical resection (eg, pancreaticoduodenectomy).^{19,20} CT-guided biopsy of pancreatic masses has a reported sensitivity up to 95%.^{21,22} However, needle-track seeding has been reported with this technique.^{23,24} In 1 study, peritoneal carcinomatosis was observed to be significantly more common among patients with pancreatic masses who underwent percutaneous sampling rather than EUS-guided biopsy (16.3% vs 2.2%, respectively, $P < .025$).²⁵

The role of magnetic resonance imaging (MRI) for evaluation of pancreatic malignancy continues to evolve.²⁶ Although CT historically has been more sensitive than MRI at the detection of pancreatic carcinoma,^{17,27} a recent study concluded that MRI was superior to CT for tumor

TABLE 3. TNM staging of pancreatic adenocarcinoma

Primary tumor (T)			
Tx	Primary tumor cannot be assessed		
T0	No evidence of primary tumor		
Tis	Carcinoma in situ		
T1	Tumor limited to the pancreas, 2 cm or less in greatest dimension		
T2	Tumor limited to the pancreas, more than 2 cm in greatest dimension		
T3	Tumor extends beyond the pancreas but without involvement of the celiac axis or superior mesenteric artery		
T4	Tumor involves the celiac axis or the superior mesenteric artery (unresectable primary tumor)		
Regional lymph nodes (N)			
NX	Regional lymph nodes cannot be assessed		
N0	No regional lymph node metastasis		
N1	Regional lymph node metastasis		
Distant metastasis (M)			
M0	No distant metastasis		
M1	Distant metastasis		
Anatomical stage/prognosis groups			
Stage 0	Tis	N0	M0
Stage IA	T1	N0	M0
Stage IB	T2	N0	M0
Stage IIA	T3	N0	M0
Stage IIB	T1	N1	M0
	T2	N1	M0
	T3	N1	M0
Stage III	T4	Any N	M0
Stage IV	Any T	Any N	M1

Reproduced with permission from the AJCC. AJCC cancer staging manual, 7th ed.⁶

detection and performed similarly for the evaluation of resectability.²⁸ MRI may reliably detect smaller, non-contour-deforming tumors compared with CT.^{13,29} MRI also more accurately detects and characterizes smaller hepatic metastases.^{30,31}

In 1 study that compared the diagnostic performance (detection, local staging) of multiphasic 64-detector CT with gadobenate dimeglumine-enhanced 3.0-T MRI in patients suspected of having pancreatic cancer, both CT and MRI were found to be equally suited for detecting and staging pancreatic cancer.³² Therefore, the choice of imaging modality for detection and staging of pancreatic cancer depends on test availability and local expertise.

Positron emission tomography and integrated PET/CT. Positron emission tomography (PET) is a technique based on differential metabolic activity of neoplastic and nonneoplastic tissue. It most often uses ¹⁸fluorodeoxyglucose (¹⁸FDG), a tracer of glucose metabolism, as an adjunct to conventional imaging. PET may be used for the diagnosis and staging of pancreatic cancer but also for postoperative surveillance to detect local and distant recurrence or metastases.³³ The development and standardization of PET integrated with CT technology

(PET/CT) has dramatically enhanced the diagnostic capabilities of these 2 modalities for pancreatic cancer, particularly for masses <2 cm in size or CT findings that are considered equivocal.^{14,34} A recent meta-analysis of 51 studies involving 3857 patients compared the diagnostic performance of ¹⁸FDG PET alone, ¹⁸FDG PET/CT, and EUS for diagnosing pancreatic cancer.³⁵ The study concluded that the pooled sensitivity estimate for ¹⁸FDG PET/CT of 90.1% (95% confidence interval [CI], 85.5%-93.6%) was significantly greater than that of ¹⁸FDG PET alone (88.4%; 95% CI, 86.3%-90.3%) or EUS (81.2%; 95% CI, 78.7%-83.5%; $P < .001$ for all comparisons). However, EUS had the highest specificity for diagnosing pancreatic cancer (93.2%; 95% CI, 91.7%-94.5%) and was significantly better than ¹⁸FDG PET (83.1%; 95% CI, 79.6%-86.3%) and ¹⁸FDG PET/CT (80.1%; 95% CI, 73.1%-86.0%; $P < .001$ for all comparisons).³⁵

Endoscopic modalities

EUS. Although EUS is more operator dependent compared with CT and MRI, it is the most sensitive test in expert hands to detect pancreatic mass lesions or pancreatic adenocarcinoma, particularly when lesions

are equivocal by CT or <2 centimeters in size.^{12,14,36-38} In a systematic review of 9 studies and 678 patients, DeWitt et al³⁹ concluded that EUS was more sensitive than CT for the detection of pancreatic adenocarcinoma (91%-100% vs 53%-91%), but the 2 studies were equivalent for loco-regional tumor staging.

EUS also allows tissue acquisition for pathology diagnosis, but sampling may not be necessary before surgery in resectable tumors.^{19,20} However, in some situations, a nonoperative pathology diagnosis in patients with otherwise resectable lesions may be desired. For example, endoscopic tissue diagnosis is helpful for the diagnosis of medically treated conditions that may mimic neoplasms or tumors such as autoimmune pancreatitis⁴⁰⁻⁴² or lymphoma, for permitting patient enrollment into a neoadjuvant chemotherapy protocol,⁴³ or for preoperative patient counseling.⁴⁴ EUS-guided tissue sampling can be performed by FNA (EUS-guided FNA [EUS-FNA]) or by EUS-guided fine-needle core biopsy (EUS-FNB). EUS-FNA has a sensitivity and specificity of up to 95% and 100%, respectively⁴⁵⁻⁴⁸ and is the preferred method for making a definitive cytology diagnosis of a pancreatic mass, even when results of other biopsy methods are negative or equivocal for malignancy.^{49,50} This approach has been shown to be cost-effective as well.⁵¹ Immediate evaluation and feedback from an on-site cytopathologist during sampling increases diagnostic yield by 10% to 15%.^{52,53} Although EUS-FNA with cytopathology usually is adequate for a diagnosis of adenocarcinoma and neuroendocrine tumors (NETs), it may not provide sufficient material for complete histologic examination for diseases such as lymphoma, well-differentiated carcinoma, or autoimmune pancreatitis.^{54,55} EUS-FNB has not been shown to be superior to EUS-FNA for determining the etiology of pancreatic masses but should be considered if EUS-FNA is nondiagnostic and a histologic diagnosis is required.^{44,56-60} FNB is technically difficult for sampling of pancreatic head masses because of the stiffness of the needle and the acute angulation of the endoscope required for biopsy from this location. More-flexible needles have been developed recently that may circumvent this problem and allow better transduodenal sampling of pancreatic head masses that require core tissue to better determine the nature of the lesion.⁶¹

Potential adverse events from EUS-guided sampling of pancreatic masses include a 0.5% to 2% risk of pancreatitis or bleeding.^{45,47,48,62,63} Tumor seeding with EUS-FNA has been reported, but the risk appears to be exceedingly small, and reports are currently limited to isolated cases.⁶⁴⁻⁶⁶ It remains unclear whether the risk of tumor seeding with EUS-FNA is related to the number of passes required to obtain adequate diagnostic samples. For pancreatic head masses, the small risk of tumor seeding with this technique is further mitigated in that any potential site of seeding would likely be included in the resection specimen. A recent study by Beane et al⁶⁷ showed

that preoperative EUS-FNA is not associated with adverse perioperative or long-term outcomes in patients undergoing distal pancreatectomy for solid neoplasms of the pancreas. Another study that evaluated survival after pancreatic cancer surgery in patients with and without prior EUS-FNA showed that survival was slightly better in the EUS-FNA group, although results were not statistically significant.⁶⁸

EUS traditionally has been performed before ERCP with stent placement because of the potential negative impact of the biliary stent on the accuracy of EUS staging.^{69,70} However, recent studies suggest that staging accuracy may not be compromised by an indwelling stent.^{71,72} EUS before ERCP also may identify unresectable pancreatic adenocarcinoma and help triage patients to biliary self-expandable metal stent (SEMS) placement at subsequent ERCP.

In patients with pancreatic cancer-related pain, EUS-guided celiac plexus neurolysis (EUS-CPN) may be considered. Performed via a transgastric approach, EUS-CPN attempts to ablate the neurons of the celiac ganglia through the injection of cytolytic agents such as alcohol or phenol. CPN is the preferred therapy in patients with cancer-related pain.⁷³ A meta-analysis by Kaufman et al⁷⁴ of 5 studies including 199 patients found that EUS-CPN was effective in alleviating abdominal pain in 72% of patients. A double-blind, controlled trial found that early EUS-CPN reduces pain and may moderate morphine consumption in patients with newly diagnosed, painful, inoperable pancreatic cancer.⁷⁵ CPN can cause transient diarrhea, hypotension, and abdominal pain. Although CPN is a very effective and safe procedure, major adverse events including reversible and permanent paralysis, organ puncture, and gastric necrosis have been described.^{76,77} A more detailed discussion of the technical and/or procedural aspects of CPN can be found elsewhere.⁷⁸

EUS-guided fiducial placement has been used to aid in image-guided radiation therapy. Fiducials can be placed with either 19-gauge or 22-gauge needles. Recently, preloaded fiducials on a 22-gauge needle have become commercially available. The procedure is very similar in concept to EUS-guided FNA and can be performed with or without fluoroscopy. The rate of adverse events from fiducial placement is comparable to that of EUS-FNA of the pancreas. Adverse events include mild pancreatitis, minor bleeding, and fiducial migration, requiring a repeat procedure.⁷⁹

EUS-guided fine-needle tattooing (EUS-FNT) has been reported to aid in the localization of pancreatic tumors in patients undergoing laparoscopic distal pancreatectomy. This is particularly helpful for cases in which abdominal imaging does not detect a lesion. In one study, the carbon particle tattoo injected by EUS-FNT was durable and visible in all 13 cases that underwent preoperative EUS-FNT.⁸⁰

ERCP. ERCP findings suggestive of a pancreatic head malignancy include strictures of both the bile and

pancreatic ducts with upstream dilation (ie, double duct sign). EUS has largely supplanted ERCP for the diagnosis of pancreatic head adenocarcinoma, and preoperative ERCP does not add further staging information beyond what may be obtained with EUS. ERCP has little value in the diagnosis or palliation of patients with adenocarcinoma of the pancreatic body and/or tail. Preoperative ERCP may also result in adverse events, thus delaying or complicating operative interventions or the potential for curative resection.⁸¹ Even in the absence of adverse events from ERCP, several studies suggest that the rate of postoperative adverse events after pancreaticoduodenectomy is higher when a preoperative ERCP is performed (with or without stent placement).⁸¹⁻⁸³ However, preoperative ERCP with biliary drainage should be performed in patients with cholangitis, severe pruritus, or possible delay in operative resection or in those patients in whom neoadjuvant chemotherapy and radiation are being considered.⁸¹

ERCP with pancreatic duct brush cytology and biopsy may be required for evaluation of suspicious pancreatic duct strictures or after nondiagnostic EUS-FNA.^{84,85} The specificity of brush cytology and biopsy approaches 100%; however, the sensitivity is only 15% to 50% for brush cytology and 33% to 50% for biopsy.⁸⁵ Other diagnostic techniques such as flow cytometry, genotyping, fluorescence in-situ hybridization, and digital imaging analysis are considered investigational.^{86,87}

Palliation of symptomatic obstructive jaundice among patients with unresectable disease can be achieved with ERCP and biliary stent placement, percutaneous stent placement, or surgical bypass.⁸⁸ Although plastic stents are less expensive than SEMs, these stents occlude after a median of 3 to 6 months because of deposition of bacterial biofilm, thus increasing the risk of recurrent jaundice and cholangitis.^{88,89} Data regarding the utility of placing multiple plastic stents to prolong patency in malignant biliary strictures are lacking.⁹⁰ Biliary SEMs may be covered or uncovered and have a significantly longer patency rate than do plastic stents.⁹¹ Although it has been suggested that the use of SEMs be reserved for patients whose estimated survival is >3 to 6 months,^{89,92} a recent Cochrane review concluded that the choice of stent type in these patients should be individualized.⁹³ A decision analysis by Chen et al⁹⁴ concluded that in patients undergoing ERCP before definitive cancer staging, the preferred initial cost-minimizing strategy is placement of a short-length SEM that does not preclude subsequent pancreaticoduodenectomy. Initial randomized trials comparing ERCP with stent placement to surgery demonstrate equal palliation of jaundice, with a more frequent need for endoscopic reintervention in the ERCP group.^{95,96} It is important, however, to note that these studies were performed before the advent of SEMs or duodenal stents for palliation of gastric outlet obstruction. A more recent study of 30 patients with metastatic pancreatic cancer and biliary obstruction randomized to surgical bypass or ERCP with SEMs found that endo-

scopic drainage is less expensive and provides better quality of life.⁹⁷ When ERCP is unsuccessful, interventional EUS techniques or percutaneous transhepatic cholangiography with stent placement can be considered where local expertise is available.^{98,99}

Patients with unresectable pancreatic adenocarcinoma who develop malignant gastric outlet obstruction can be palliated through surgical bypass, percutaneous or endoscopic decompression using gastrostomy, or endoscopic gastroduodenal SEMs placement.^{100,101} Endoscopic gastroduodenal SEMs placement can be delivered either through or alongside the endoscope with fluoroscopic guidance. A more detailed discussion on the endoscopic management of malignant gastric outlet obstruction can be found in another ASGE Standards of Practice document.¹⁰²

NEUROENDOCRINE TUMORS (NETS) OF THE PANCREAS

NETs of the pancreas are rare tumors thought to arise from neuroendocrine cells within pancreatic islets. The majority of pancreatic NETs are sporadic, but about 10% to 30% of patients with NETs have multiple endocrine neoplasia type 1 syndrome.¹⁰³ The majority (50%-60%) of pancreatic NETs are nonfunctioning.¹⁰⁴ Nonfunctioning NETs present with a pancreatic mass, and their presentation may mimic that of adenocarcinoma, although biliary obstruction is uncommon. Functioning NETs are classified according to the hormone secreted by the tumor and include insulinomas, gastrinomas, VIPomas, glucagonomas, and somatostatinomas, and they may present with their associated hormone syndromes. Histologically, NETs are graded based on mitotic count and Ki-67 index. Pancreatic NETs are staged by the same TNM staging system used for exocrine pancreatic tumors (Table 3).⁶ Although NETs often are detected incidentally by cross-sectional imaging, EUS also plays an important role in detection and confirmation of the diagnosis.¹⁰⁵⁻¹⁰⁹

Radiologic modalities

The TUS appearance of pancreatic NETs is typically a well-defined, hypoechoic, round mass that may demonstrate a hyperechoic halo or may distort the gland.¹¹⁰ Pancreatic NETs are most commonly detected on CT as small solid masses, but, rarely, they can be cystic. On before-contrast images, pancreatic NETs are isodense with the pancreatic parenchyma but enhance significantly after contrast, particularly in the arterial phase. This is in contrast to adenocarcinoma, which typically appears hypointense after contrast. On MRI, pancreatic NETs exhibit low signal intensity on T1-weighted sequences and high signal intensity on T2-weighted sequences. After gadolinium administration, pancreatic NETs enhance homogeneously, although larger tumors may be heterogeneous, and rim enhancement may be seen. Somatostatin receptor

scintigraphy can be a useful tool to localize NETs and to detect metastases.¹¹¹

Endoscopic modalities

EUS. Pancreatic NETs typically appear solid, hypoechoic, and homogenous, with distinct margins on EUS. Rarely they may be cystic and confused with other cystic lesions of the pancreas.³ EUS is superior to TUS, CT, MRI, and somatostatin receptor scintigraphy for the localization of NETs, with a sensitivity of 82% to 93%.^{105-109,111} Despite improved cross-sectional imaging, EUS remains superior to CT for detection of pancreatic NETs, particularly for insulinomas.¹⁰⁷ EUS also permits tissue acquisition, which is particularly useful in small or nonfunctioning tumors.^{107,109,112}

ERCP. ERCP does not have a primary role in the diagnosis of pancreatic NETs. For rare lesions that compress the pancreatic duct or cause biliary obstruction, ERCP may have an important therapeutic role.¹¹³

SOLID PSEUDOPAPILLARY TUMORS (SPTs)

SPTs of the pancreas are rare tumors that predominantly affect young women in the third decade of life. Unlike pancreatic adenocarcinoma, these tumors have a low malignant potential, and usually surgery is curative.¹¹⁴ Rarely, SPTs may develop in extrapancreatic locations. The most common presentation is pain or a palpable abdominal mass, but other nonspecific symptoms such as nausea and vomiting may occur. SPTs are often large, with a median size of 6 cm to 7 cm, and frequently they are discovered incidentally.^{114,115} Although radiologic and endoscopic imaging are important in the evaluation of these tumors, the diagnosis of SPTs can be difficult. In the largest series of SPTs reported to date, only 52 of 718 cases (7%) had a preoperative diagnosis confirmed by biopsy.¹¹⁴

Radiologic modalities

On TUS, SPTs appear as well-defined, heterogeneous, solid masses that may contain areas of cystic degeneration or hemorrhage.¹¹⁶ Data are lacking regarding the sensitivity and specificity of TUS for diagnosing SPTs. The typical CT appearance of an SPT consists of a large, well-circumscribed, heterogeneous mass with solid and cystic components. Areas of internal hemorrhage and a capsule also may be visualized.¹¹⁷ These tumors are typically avascular or hypovascular. The overall appearance of an SPT on MRI is similar to that of CT, but MRI allows better identification of cystic portions or hemorrhage within the tumor.^{117,118}

Endoscopic modalities

EUS. In a retrospective, multicenter study of 28 cases, EUS-FNA confirmed the diagnosis of SPT in 75% (21/28).¹¹⁹ Sonographically, SPTs were echo poor and

solid in 50% (14/28), mixed solid and cystic in 39% (11/28), and cystic alone in 11% (3/28). Irregular calcification was seen in 21% (6/28). Other reports have supported the role of EUS-FNA in the diagnosis of SPTs.^{120,121} Preoperative sampling of SPTs may not be necessary because both a positive diagnosis and nondiagnostic specimen do not change planned surgical management, which provides the best chance for long-term cure.¹²²

METASTATIC DISEASE

Metastases to the pancreas are rare and do not show predilection for any region of the pancreas.¹²³ The most common metastasis to the pancreas is renal cell carcinoma, but a variety of other cancers including melanoma, breast, lung, and colorectal cancers have been reported. There is often a long delay between the original diagnosis and the appearance of pancreatic metastasis, and multiple metastases may be present at the time of diagnosis.¹²⁴ Metastases to the pancreas can result in biliary or pancreatic duct obstruction, pain, or pancreatitis and may be resectable.^{125,126} CT and MRI findings may mimic primary adenocarcinoma of the pancreas but are more likely to show peripheral or homogenous contrast enhancement rather than the hypoenhancement of primary pancreatic adenocarcinoma.^{127,128} The roles of EUS and ERCP in metastatic disease of the pancreas are similar to those described for pancreatic adenocarcinoma.¹²⁹ Diagnostic EUS findings in metastatic disease may be different than in pancreatic adenocarcinoma. DeWitt et al¹³⁰ reviewed the EUS-FNA features in 24 patients with metastases to the pancreas and found that metastatic lesions were more likely to have well-defined margins than primary pancreatic adenocarcinoma. A recent report found that EUS-FNA confirmed the origin of metastasis in the majority of cases.¹³¹ Clinical history of a prior malignancy should prompt consideration of a potential metastatic lesion to the pancreas, therefore extra biopsies for immunostains or core biopsy should be considered.¹³² EUS-FNA by using a 22-gauge needle with immunostains has excellent diagnostic yield in patients with unusual, neuroendocrine, and metastatic lesions of the pancreas.¹³² The ability to procure a core tissue biopsy may even enhance the EUS-FNA potential to diagnose these lesions in the future.

LYMPHOMA

Primary lymphoma of the pancreas is extremely rare and can present as a focal or diffuse mass, frequently mimicking more common neoplasms such as adenocarcinoma or inflammatory processes such as pancreatitis.¹³³⁻¹³⁶ In 1 study, Khashab et al¹³⁷ showed that EUS-FNA with flow cytometry was superior to EUS-FNA without flow cytometry in the

evaluation of 16 patients suspected to have pancreatic primary pancreatic lymphoma.

The endoscopic evaluation is identical to that of the more common pancreatic neoplasms. If lymphoma is suspected (eg, coexistent abdominal lymphadenopathy or other findings), a cytologic sample for flow cytometry or core biopsy should be obtained.

SCREENING FOR PANCREATIC CANCER

In view of the dismal prognosis of pancreatic cancer at the time of diagnosis, screening programs have been proposed in the last decade in an attempt to detect pancreatic cancer at an early stage and potentially improve survival. Population-based endoscopic or image-based screening programs are not feasible or cost-effective, given the relatively low incidence of the disease. However, screening may be desirable in high-risk individuals. High-risk individuals include patients with hereditary pancreatitis, Peutz-Jeghers syndrome, Lynch syndrome, familial breast-ovarian cancer syndrome, familial atypical multiple mole melanoma, and familial pancreatic cancer syndrome. Accumulating data indicate that clinically available abdominal imaging tests such as EUS and MRI and/or MRCP can detect asymptomatic precursor lesions, such as intraductal papillary mucinous neoplasm, PanIN, and invasive malignant pancreatic neoplasms, such as ductal adenocarcinoma, in individuals with an inherited predisposition. Two large studies in screening in high-risk individuals reported their results.^{138,139} One study from the United States reported that screening of asymptomatic high-risk individuals frequently (42% of 216 patients) detects small pancreatic cysts, including curable, noninvasive, high-grade neoplasms. EUS and MRI detect pancreatic lesions better than CT.¹³⁹ A Dutch study recently reported that EUS and/or MRI detected clinically relevant pancreatic lesions in 6% of high-risk individuals. Both imaging techniques were complementary. MRI was found to be very sensitive for the detection of cystic lesions of any size. MRI, however, might have some important limitations with regard to the timely detection of solid lesions.¹³⁸ Screening is best performed within research protocols or registries involving multidisciplinary teams with expertise in genetics, gastroenterology, radiology, surgery, and pathology.¹⁴⁰

RECOMMENDATIONS

- We recommend that imaging evaluation of patients with suspected solid pancreatic neoplasia include EUS and multidetector pancreas protocol CT scans with selective use of MRI and PET-CT when appropriate. ⊕⊕⊕⊕
- We recommend that EUS be performed for evaluation of pancreatic masses and suspected malignancy, partic-

ularly when CT detection or evaluation of resectability is equivocal. ⊕⊕⊕⊕

- We recommend that biopsy of a suspected primary or metastatic pancreatic tumor should be individualized based on need for preoperative chemotherapy, resectability, and feasibility of surgery. ⊕⊕⊕⊕
- We suggest that EUS-guided celiac plexus neurolysis be considered in patients with pancreatic cancer-related pain. ⊕⊕⊕○
- We do not recommend preoperative ERCP in patients with obstructive jaundice because of resectable adenocarcinoma of the pancreas in the absence of cholangitis unless a substantial delay in operative resection of a symptomatic patient is anticipated. ⊕⊕⊕○
- We recommend that patients with symptomatic, unresectable adenocarcinoma of the pancreas with biliary and/or gastroduodenal obstruction undergo attempted palliation with endoscopic stent placement as the preferred therapeutic modality. ⊕⊕⊕○
- We recommend EUS ± FNA for localization and characterization of suspected pancreatic neuroendocrine tumors and metastatic solid pancreatic neoplasia. ⊕⊕⊕○
- We suggest EUS-guided fiducial placement into a pancreatic malignancy if image-guided radiation therapy is considered. ⊕⊕⊕○
- We suggest that screening with EUS and MRCP should be offered to high-risk individuals for pancreatic cancer. ⊕⊕○○

DISCLOSURE

K. Chathadi is a member of the speakers bureau for Boston Scientific. D. Fisber is a consultant for Epigenomics Inc. J. DeWitt is a consultant for Olympus America and Boston Scientific. All other authors disclosed no financial relationships relevant to this publication.

Abbreviations: 3-D, 3-dimensional; ¹⁸FDG, ¹⁸fluorodeoxyglucose; ASGE, American Society for Gastrointestinal Endoscopy; CPN, celiac plexus neurolysis; EUS-FNA, EUS-guided FNA; EUS-FNB, EUS-guided fine-needle core biopsy; EUS-FNT, EUS-guided fine-needle tattooing; MRI, magnetic resonance imaging; NET, neuroendocrine tumor; PET, positron emission tomography; SEMS, self-expandable metal stent; SPT, solid pseudopapillary tumor; TUS, transabdominal US.

REFERENCES

1. ASGE Standards of Practice committee; Adler DG, Baron TH, Davila RE, et al. ASGE guideline: the role of ERCP in diseases of the biliary tract and the pancreas. *Gastrointest Endosc* 2005;62:1-8.
2. Guyatt G, Oxman AD, Akl EA, et al. GRADE guidelines: 1. Introduction- GRADE evidence profiles and summary of findings tables. *J Clin Epidemiol* 2011;64:383-94.
3. ASGE Standards of Practice committee; Jacobson BC, Baron TH, Adler DG, et al. ASGE guideline: The role of endoscopy in the diagnosis and the management of cystic lesions and inflammatory fluid collections of the pancreas. *Gastrointest Endosc* 2005;61:363-70.

4. Partyka K, Maupin KA, Brand RE, et al. Diverse monoclonal antibodies against the CA 19-9 antigen show variation in binding specificity with consequences for clinical interpretation. *Proteomics* 2012;12:2212-20.
5. Winter JM, Yeo CJ, Brody JR. Diagnostic, prognostic, and predictive biomarkers in pancreatic cancer. *J Surg Oncol* 2013;107:15-22.
6. Edge S, Byrd DR, Compton CC, et al, eds. *AJCC Cancer Staging Manual*, 7th ed. New York: Springer; 2010.
7. American Cancer Society. *Cancer Facts & Figures 2015*. Atlanta: American Cancer Society; 2015.
8. Hidalgo M. Pancreatic cancer. *N Engl J Med* 2010;362:1605-17.
9. Freeny PC. Pancreatic carcinoma: What is the best imaging test? *Pancreatol* 2001;1:604-9.
10. Hirooka Y, Goto H, Ito A, et al. Recent advances in US diagnosis of pancreatic cancer. *Hepatogastroenterology* 2001;48:916-22.
11. Takeda K, Goto H, Hirooka Y, et al. Contrast-enhanced transabdominal ultrasonography in the diagnosis of pancreatic mass lesions. *Acta Radiol* 2003;44:103-6.
12. Bronstein YL, Loyer EM, Kaur H, et al. Detection of small pancreatic tumors with multiphase helical CT. *AJR Am J Roentgenol* 2004;182:619-23.
13. Saisho H, Yamaguchi T. Diagnostic imaging for pancreatic cancer: computed tomography, magnetic resonance imaging, and positron emission tomography. *Pancreas* 2004;28:273-8.
14. Sahani DV, Bonaffini PA, Catalano OA, et al. State-of-the-art PET/CT of the pancreas: current role and emerging indications. *Radiographics* 2012;32:1133-58; discussion 58-60.
15. Valls C, Andia E, Sanchez A, et al. Dual-phase helical CT of pancreatic adenocarcinoma: assessment of resectability before surgery. *AJR Am J Roentgenol* 2002;178:821-6.
16. Soriano A, Castells A, Ayuso C, et al. Preoperative staging and tumor resectability assessment of pancreatic cancer: prospective study comparing endoscopic ultrasonography, helical computed tomography, magnetic resonance imaging, and angiography. *Am J Gastroenterol* 2004;99:492-501.
17. Mortelet KJ, Ji H, Ros PR. CT and magnetic resonance imaging in pancreatic and biliary tract malignancies. *Gastrointest Endosc* 2002;56:S206-12.
18. Raman SP, Horton KM, Fishman EK. Multimodality imaging of pancreatic cancer-computed tomography, magnetic resonance imaging, and positron emission tomography. *Cancer J* 2012;18:511-22.
19. Hartwig W, Schneider L, Diener MK, et al. Preoperative tissue diagnosis for tumours of the pancreas. *Brit J Surg* 2009;96:5-20.
20. Wolfgang CL, Herman JM, Laheru DA, et al. Recent progress in pancreatic cancer. *CA-Cancer J Clin* 2013;63:318-48.
21. Erturk SM, Mortelet KJ, Tuncali K, et al. Fine-needle aspiration biopsy of solid pancreatic masses: comparison of CT and endoscopic sonography guidance. *AJR Am J Roentgenol* 2006;187:1531-5.
22. Paulsen SD, Nghiem HV, Negussie E, et al. Evaluation of imaging-guided core biopsy of pancreatic masses. *AJR Am J Roentgenol* 2006;187:769-72.
23. Bergenfeldt M, Genell S, Lindholm K, et al. Needle-tract seeding after percutaneous fine-needle biopsy of pancreatic carcinoma. Case report. *Acta Chir Scand* 1988;154:77-9.
24. Warshaw AL. Implications of peritoneal cytology for staging of early pancreatic cancer. *Am J Surg* 1991;161:26-9; discussion 9-30.
25. Micames C, Jowell PS, White R, et al. Lower frequency of peritoneal carcinomatosis in patients with pancreatic cancer diagnosed by EUS-guided FNA vs. percutaneous FNA. *Gastrointest Endosc* 2003;58:690-5.
26. Vachiranubhap B, Kim YH, Balci NC, et al. Magnetic resonance imaging of adenocarcinoma of the pancreas. *Top Magn Reson Imaging* 2009;20:3-9.
27. Schima W, Fugger R, Schober E, et al. Diagnosis and staging of pancreatic cancer: comparison of mangafodipir trisodium-enhanced MR imaging and contrast-enhanced helical hydro-CT. *AJR Am J Roentgenol* 2002;179:717-24.
28. Park HS, Lee JM, Choi HK, et al. Preoperative evaluation of pancreatic cancer: comparison of gadolinium-enhanced dynamic MRI with MR cholangiopancreatography versus MDCT. *J Magn Reson Imaging* 2009;30:586-95.
29. Vellet AD, Romano W, Bach DB, et al. Adenocarcinoma of the pancreatic ducts: comparative evaluation with CT and MR imaging at 1.5 T. *Radiology* 1992;183:87-95.
30. Holalkere NS, Sahani DV, Blake MA, et al. Characterization of small liver lesions: added role of MR after MDCT. *J Comput Assist Tomogr* 2006;30:591-6.
31. Sahani DV, Shah ZK, Catalano OA, et al. Radiology of pancreatic adenocarcinoma: current status of imaging. *J Gastroenterol Hepatol* 2008;23:23-33.
32. Koelblinger C, Ba-Ssalamah A, Goetzinger P, et al. Gadobenate dimeglumine-enhanced 3.0-T MR imaging versus multiphase 64-detector row CT: prospective evaluation in patients suspected of having pancreatic cancer. *Radiology* 2011;259:757-66.
33. Murakami K. FDG-PET for hepatobiliary and pancreatic cancer: advances and current limitations. *World J Clin Oncol* 2011;2:229-36.
34. Delbeke D, Martin WH. Update of PET and PET/CT for hepatobiliary and pancreatic malignancies. *HPB (Oxford)* 2005;7:166-79.
35. Tang S, Huang G, Liu J, et al. Usefulness of 18F-FDG PET, combined FDG-PET/CT and EUS in diagnosing primary pancreatic carcinoma: a meta-analysis. *Eur J Radiol* 2011;78:142-50.
36. Muller MF, Meyenberger C, Bertschinger P, et al. Pancreatic tumors: evaluation with endoscopic US, CT, and MR imaging. *Radiology* 1994;190:745-51.
37. DeWitt J, Devereaux B, Chriswell M, et al. Comparison of endoscopic ultrasonography and multidetector computed tomography for detecting and staging pancreatic cancer. *Ann Intern Med* 2004;141:753-63.
38. Gress FG, Hawes RH, Savides TJ, et al. Role of EUS in the preoperative staging of pancreatic cancer: a large single-center experience. *Gastrointest Endosc* 1999;50:786-91.
39. Dewitt J, Devereaux BM, Lehman GA, et al. Comparison of endoscopic ultrasound and computed tomography for the preoperative evaluation of pancreatic cancer: a systematic review. *Clin Gastroenterol Hepatol* 2006;4:717-25; quiz 664.
40. Gardner TB, Levy MJ, Takahashi N, et al. Misdiagnosis of autoimmune pancreatitis: a caution to clinicians. *Am J Gastroenterol* 2009;104:1620-3.
41. Takahashi N, Fletcher JG, Hough DM, et al. Autoimmune pancreatitis: differentiation from pancreatic carcinoma and normal pancreas on the basis of enhancement characteristics at dual-phase CT. *AJR Am J Roentgenol* 2009;193:479-84.
42. Ghazale A, Chari ST, Smyrk TC, et al. Value of serum IgG4 in the diagnosis of autoimmune pancreatitis and in distinguishing it from pancreatic cancer. *Am J Gastroenterol* 2007;102:1646-53.
43. Crane CH, Varadhachary G, Wolff RA, et al. The argument for preoperative chemoradiation for localized, radiographically resectable pancreatic cancer. *Best Pract Res Clin Gastroenterol* 2006;20:365-82.
44. Levy MJ, Reddy RP, Wiersema MJ, et al. EUS-guided trucut biopsy in establishing autoimmune pancreatitis as the cause of obstructive jaundice. *Gastrointest Endosc* 2005;61:467-72.
45. Lai R, Stanley MW, Bardales R, et al. Endoscopic ultrasound-guided pancreatic duct aspiration: diagnostic yield and safety. *Endoscopy* 2002;34:715-20.
46. Varadarajulu S, Tamhane A, Eloubeidi MA. Yield of EUS-guided FNA of pancreatic masses in the presence or the absence of chronic pancreatitis. *Gastrointest Endosc* 2005;62:728-36, quiz 51, 53.
47. Eloubeidi MA, Jhala D, Chhieng DC, et al. Yield of endoscopic ultrasound-guided fine-needle aspiration biopsy in patients with suspected pancreatic carcinoma. *Cancer* 2003;99:285-92.
48. Eloubeidi MA, Chen VK, Eltoun IA, et al. Endoscopic ultrasound-guided fine needle aspiration biopsy of patients with suspected pancreatic cancer: diagnostic accuracy and acute and 30-day complications. *Am J Gastroenterol* 2003;98:2663-8.

49. Gress F, Gottlieb K, Sherman S, et al. Endoscopic ultrasonography-guided fine-needle aspiration biopsy of suspected pancreatic cancer. *Ann Intern Med* 2001;134:459-64.
50. Harewood GC, Wiersema MJ. Endosonography-guided fine needle aspiration biopsy in the evaluation of pancreatic masses. *Am J Gastroenterol* 2002;97:1386-91.
51. Chen VK, Arguedas MR, Kilgore ML, et al. A cost-minimization analysis of alternative strategies in diagnosing pancreatic cancer. *Am J Gastroenterol* 2004;99:2223-34.
52. Klapman JB, Logrono R, Dye CE, et al. Clinical impact of on-site cytopathology interpretation on endoscopic ultrasound-guided fine needle aspiration. *Am J Gastroenterol* 2003;98:1289-94.
53. Layfield LJ, Bentz JS, Gopez EV. Immediate on-site interpretation of fine-needle aspiration smears: a cost and compensation analysis. *Cancer* 2001;93:319-22.
54. Thomas T, Kaye PV, Rangunath K, et al. Efficacy, safety, and predictive factors for a positive yield of EUS-guided Trucut biopsy: a large tertiary referral center experience. *Am J Gastroenterol* 2009;104:584-91.
55. Levy MJ. Endoscopic ultrasound-guided trucut biopsy of the pancreas: prospects and problems. *Pancreatology* 2007;7:163-6.
56. Shah SM, Ribeiro A, Levi J, et al. EUS-guided fine needle aspiration with and without trucut biopsy of pancreatic masses. *JOP* 2008;9:422-30.
57. Varadarajulu S, Fraig M, Schmulewitz N, et al. Comparison of EUS-guided 19-gauge Trucut needle biopsy with EUS-guided fine-needle aspiration. *Endoscopy* 2004;36:397-401.
58. Aithal GP, Anagnostopoulos GK, Tam W, et al. EUS-guided tissue sampling: comparison of "dual sampling" (Trucut biopsy plus FNA) with "sequential sampling" (Trucut biopsy and then FNA as required). *Endoscopy* 2007;39:725-30.
59. Larghi A, Verna EC, Stavropoulos SN, et al. EUS-guided trucut needle biopsies in patients with solid pancreatic masses: a prospective study. *Gastrointest Endosc* 2004;59:185-90.
60. Mizuno N, Bhatia V, Hosoda W, et al. Histological diagnosis of autoimmune pancreatitis using EUS-guided trucut biopsy: a comparison study with EUS-FNA. *J Gastroenterol* 2009;44:742-50.
61. Varadarajulu S, Bang JY, Hebert-Magee S. Assessment of the technical performance of the flexible 19-gauge EUS-FNA needle. *Gastrointest Endosc* 2012;76:336-43.
62. Eloubeidi MA, Tamhane A, Varadarajulu S, et al. Frequency of major complications after EUS-guided FNA of solid pancreatic masses: a prospective evaluation. *Gastrointest Endosc* 2006;63:622-9.
63. Eloubeidi MA, Gress FG, Savides TJ, et al. Acute pancreatitis after EUS-guided FNA of solid pancreatic masses: a pooled analysis from EUS centers in the United States. *Gastrointest Endosc* 2004;60:385-9.
64. Paquin SC, Garipey G, Lepanto L, et al. A first report of tumor seeding because of EUS-guided FNA of a pancreatic adenocarcinoma. *Gastrointest Endosc* 2005;61:610-1.
65. Chong A, Venugopal K, Segarajasingam D, et al. Tumor seeding after EUS-guided FNA of pancreatic tail neoplasia. *Gastrointest Endosc* 2011;74:933-5.
66. Ahmed K, Sussman JJ, Wang J, et al. A case of EUS-guided FNA-related pancreatic cancer metastasis to the stomach. *Gastrointest Endosc* 2011;74:231-3.
67. Beane JD, House MG, Cote GA, et al. Outcomes after preoperative endoscopic ultrasonography and biopsy in patients undergoing distal pancreatectomy. *Surgery* 2011;150:844-53.
68. Ngamruengphong S, Swanson KM, Shah ND, et al. Preoperative endoscopic ultrasound-guided fine needle aspiration does not impair survival of patients with resected pancreatic cancer. *Gut* 2015;64:1105-10.
69. Chen CH, Tseng LJ, Yang CC, et al. Preoperative evaluation of periampullary tumors by endoscopic sonography, transabdominal sonography, and computed tomography. *J Clin Ultrasound* 2001;29:313-21.
70. Cannon ME, Carpenter SL, Elta GH, et al. EUS compared with CT, magnetic resonance imaging, and angiography and the influence of biliary stenting on staging accuracy of ampullary neoplasms. *Gastrointest Endosc* 1999;50:27-33.
71. Fisher JM, Gordon SR, Gardner TB. The impact of prior biliary stenting on the accuracy and complication rate of endoscopic ultrasound fine-needle aspiration for diagnosing pancreatic adenocarcinoma. *Pancreas* 2011;40:21-4.
72. Shami VM, Mahajan A, Sundaram V, et al. Endoscopic ultrasound staging is adversely affected by placement of a self-expandable metal stent: fact or fiction? *Pancreas* 2008;37:396-8.
73. Chak A. What is the evidence for EUS-guided celiac plexus block/neurolysis? *Gastrointest Endosc* 2009;69:S172-3.
74. Kaufman M, Singh G, Das S, et al. Efficacy of endoscopic ultrasound-guided celiac plexus block and celiac plexus neurolysis for managing abdominal pain associated with chronic pancreatitis and pancreatic cancer. *J Clin Gastroenterol* 2010;44:127-34.
75. Wyse JM, Carone M, Paquin SC, et al. Randomized, double-blind, controlled trial of early endoscopic ultrasound-guided celiac plexus neurolysis to prevent pain progression in patients with newly diagnosed, painful, inoperable pancreatic cancer. *J Clin Oncol* 2011;29:3541-6.
76. Fujii L, Clain JE, Morris JM, et al. Anterior spinal cord infarction with permanent paralysis following endoscopic ultrasound-guided celiac plexus neurolysis. *Endoscopy* 2012;44(suppl 2)UCTN: E265-6.
77. Loeve US, Mortensen MB. Lethal necrosis and perforation of the stomach and the aorta after multiple EUS-guided celiac plexus neurolysis procedures in a patient with chronic pancreatitis. *Gastrointest Endosc* 2013;77:151-2.
78. Levy MJ, Wiersema MJ. Endoscopic ultrasound-guided pain control for intra-abdominal cancer. *Gastroenterol Clin N* 2006;35:153-65.
79. Luz LP, Al-Haddad MA, Sey MS, et al. Applications of endoscopic ultrasound in pancreatic cancer. *World J Gastroenterol* 2014;20:7808-18.
80. Lennon AM, Newman N, Makary MA, et al. EUS-guided tattooing before laparoscopic distal pancreatic resection (with video). *Gastrointest Endosc* 2010;72:1089-94.
81. Isenberg G, Gouma DJ, Pisters PW. The on-going debate about perioperative biliary drainage in jaundiced patients undergoing pancreaticoduodenectomy. *Gastrointest Endosc* 2002;56:310-5.
82. van der Gaag NA, Rauws EA, van Eijck CH, et al. Preoperative biliary drainage for cancer of the head of the pancreas. *N Engl J Med* 2010;362:129-37.
83. Baron TH, Kozarek RA. Preoperative biliary stents in pancreatic cancer—proceed with caution. *N Engl J Med* 2010;362:170-2.
84. Hawes RH. Diagnostic and therapeutic uses of ERCP in pancreatic and biliary tract malignancies. *Gastrointest Endosc* 2002;56:S201-5.
85. De Bellis M, Sherman S, Fogel EL, et al. Tissue sampling at ERCP in suspected malignant biliary strictures (Part 1). *Gastrointest Endosc* 2002;56:552-61.
86. Pausawasdi N, Scheiman J. Endoscopic evaluation and palliation of pancreatic adenocarcinoma: current and future options. *Curr Opin Gastroenterol* 2007;23:515-21.
87. Layfield LJ, Ehya H, Filie AC, et al. Utilization of ancillary studies in the cytologic diagnosis of biliary and pancreatic lesions: the Papanicolaou Society of Cytopathology guidelines for pancreatobiliary cytology. *Diagn Cytopathol* 2014;42:351-62.
88. Baron TH. Palliation of malignant obstructive jaundice. *Gastroenterol Clin North Am* 2006;35:101-12.
89. Kaassis M, Boyer J, Dumas R, et al. Plastic or metal stents for malignant stricture of the common bile duct? Results of a randomized prospective study. *Gastrointest Endosc* 2003;57:178-82.
90. Lawrence C, Romagnuolo J, Payne KM, et al. Low symptomatic premature stent occlusion of multiple plastic stents for benign biliary strictures: comparing standard and prolonged stent change intervals. *Gastrointest Endosc* 2010;72:558-63.

91. Davids PH, Groen AK, Rauws EA, et al. Randomised trial of self-expanding metal stents versus polyethylene stents for distal malignant biliary obstruction. *Lancet* 1992;340:1488-92.
92. Yeoh KG, Zimmerman MJ, Cunningham JT, et al. Comparative costs of metal versus plastic biliary stent strategies for malignant obstructive jaundice by decision analysis. *Gastrointest Endosc* 1999;49:466-71.
93. Moss AC, Morris E, Mac Mathuna P. Palliative biliary stents for obstructing pancreatic carcinoma. *Cochrane Database Syst Rev* 2006; CD004200.
94. Chen VK, Arguedas MR, Baron TH. Expandable metal biliary stents before pancreaticoduodenectomy for pancreatic cancer: a Monte-Carlo decision analysis. *Clin Gastroenterol Hepatol* 2005;3:1229-37.
95. Shepherd HA, Royle G, Ross AP, et al. Endoscopic biliary endoprosthesis in the palliation of malignant obstruction of the distal common bile duct: a randomized trial. *Brit J Surg* 1988;75:1166-8.
96. Smith AC, Dowsett JF, Russell RC, et al. Randomised trial of endoscopic stenting versus surgical bypass in malignant low bile duct obstruction. *Lancet* 1994;344:1655-60.
97. Artifon EL, Sakai P, Cunha JE, et al. Surgery or endoscopy for palliation of biliary obstruction due to metastatic pancreatic cancer. *Am J Gastroenterol* 2006;101:2031-7.
98. ASGE Technology Committee; Kaul V, Adler DG, Conway JD, et al. Interventional EUS. *Gastrointest Endosc* 2010;72:1-4.
99. Harewood GC, Baron TH, LeRoy AJ, et al. Cost-effectiveness analysis of alternative strategies for palliation of distal biliary obstruction after a failed cannulation attempt. *Am J Gastroenterol* 2002;97:1701-7.
100. Adler DG, Baron TH. Endoscopic palliation of malignant gastric outlet obstruction using self-expanding metal stents: experience in 36 patients. *Am J Gastroenterol* 2002;97:72-8.
101. Yim HB, Jacobson BC, Saltzman JR, et al. Clinical outcome of the use of enteral stents for palliation of patients with malignant upper GI obstruction. *Gastrointest Endosc* 2001;53:329-32.
102. ASGE Standards of Practice Committee; Fukami N, Anderson MA, Khan K, et al. The role of endoscopy in gastroduodenal obstruction and gastroparesis. *Gastrointest Endosc* 2011;74:13-21.
103. Alexakis N, Neoptolemos JP. Pancreatic neuroendocrine tumours. *Best Pract Res Clin Gastroenterol* 2008;22:183-205.
104. Vagefi PA, Razo O, Deshpande V, et al. Evolving patterns in the detection and outcomes of pancreatic neuroendocrine neoplasms: the Massachusetts General Hospital experience from 1977 to 2005. *Arch Surg* 2007;142:347-54.
105. Ardengh JC, Rosenbaum P, Ganc AJ, et al. Role of EUS in the preoperative localization of insulinomas compared with spiral CT. *Gastrointest Endosc* 2000;51:552-5.
106. Anderson MA, Carpenter S, Thompson NW, et al. Endoscopic ultrasound is highly accurate and directs management in patients with neuroendocrine tumors of the pancreas. *Am J Gastroenterol* 2000;95:2271-7.
107. Khashab MA, Yong E, Lennon AM, et al. EUS is still superior to multidetector computerized tomography for detection of pancreatic neuroendocrine tumors. *Gastrointest Endosc* 2011;73:691-6.
108. Sugiyama M, Abe N, Izumisato Y, et al. Differential diagnosis of benign versus malignant nonfunctioning islet cell tumors of the pancreas: the roles of EUS and ERCP. *Gastrointest Endosc* 2002;55:115-9.
109. ASGE Standards of Practice Committee; Gan SI, Rajan E, Adler DG, et al. Role of EUS. *Gastrointest Endosc* 2007;66:425-34.
110. Rockall AG, Reznick RH. Imaging of neuroendocrine tumours (CT/MR/US). *Best Pract Res Clin Endocrinol Metab* 2007;21:43-68.
111. Zimmer T, Ziegler K, Bader M, et al. Localisation of neuroendocrine tumours of the upper gastrointestinal tract. *Gut* 1994;35:471-5.
112. Pais SA, Al-Haddad M, Mohamadnejad M, et al. EUS for pancreatic neuroendocrine tumors: a single-center, 11-year experience. *Gastrointest Endosc* 2010;71:1185-93.
113. ASGE Standards of Practice Committee; Chathadi KV, Khashab MA, Acosta RD, et al. The role of endoscopy in ampullary and duodenal adenomas. *Gastrointest Endosc* 2015;82:773-81.
114. Papavramidis T, Papavramidis S. Solid pseudopapillary tumors of the pancreas: review of 718 patients reported in English literature. *J Am Coll Surg* 2005;200:965-72.
115. de Castro SM, Singhal D, Aronson DC, et al. Management of solid-pseudopapillary neoplasms of the pancreas: a comparison with standard pancreatic neoplasms. *World J Surg* 2007;31:1130-5.
116. Buetow PC, Buck JL, Pantongrag-Brown L, et al. Solid and papillary epithelial neoplasm of the pancreas: imaging-pathologic correlation on 56 cases. *Radiology* 1996;199:707-11.
117. Yu MH, Lee JY, Kim MA, et al. MR imaging features of small solid pseudopapillary tumors: retrospective differentiation from other small solid pancreatic tumors. *AJR Am J Roentgenol* 2010;195:1324-32.
118. Yao X, Ji Y, Zeng M, et al. Solid pseudopapillary tumor of the pancreas: cross-sectional imaging and pathologic correlation. *Pancreas* 2010;39:486-91.
119. Jani N, Dewitt J, Eloubeidi M, et al. Endoscopic ultrasound-guided fine-needle aspiration for diagnosis of solid pseudopapillary tumors of the pancreas: a multicenter experience. *Endoscopy* 2008;40:200-3.
120. Bardales RH, Centeno B, Mallery JS, et al. Endoscopic ultrasound-guided fine-needle aspiration cytology diagnosis of solid-pseudopapillary tumor of the pancreas: a rare neoplasm of elusive origin but characteristic cytomorphologic features. *Am J Clin Pathol* 2004;121:654-62.
121. Master SS, Savides TJ. Diagnosis of solid-pseudopapillary neoplasm of the pancreas by EUS-guided FNA. *Gastrointest Endosc* 2003;57:965-8.
122. Levy P, Auber A, Ruzsiewicz P. Do not biopsy solid pseudopapillary tumors of the pancreas! *Endoscopy* 2008;40:959; author reply 60.
123. Minni F, Casadei R, Perenze B, et al. Pancreatic metastases: observations of three cases and review of the literature. *Pancreatology* 2004;4:509-20.
124. Baron TH. Endoscopic US for metastases to the pancreas: chasing the satellites. *Gastrointest Endosc* 2005;61:697-9.
125. Jarufe N, McMaster P, Mayer AD, et al. Surgical treatment of metastases to the pancreas. *Surgeon* 2005;3:79-83.
126. Sperti G, Pasquali C, Liessi G, et al. Pancreatic resection for metastatic tumors to the pancreas. *J Surg Oncol* 2003;83:161-6; discussion 6.
127. Tsitouridis I, Diamantopoulou A, Michaelides M, et al. Pancreatic metastases: CT and MRI findings. *Diagn Interv Radiol* 2010;16:45-51.
128. Moon SG, Han JK, Kim TK, et al. Biliary obstruction in metastatic disease: thin-section helical CT findings. *Abdom Imaging* 2003;28:45-52.
129. Valiozis I, Zekry A, Williams SJ, et al. Palliation of hilar biliary obstruction from colorectal metastases by endoscopic stent insertion. *Gastrointest Endosc* 2000;51:412-7.
130. DeWitt J, Jowell P, Leblanc J, et al. EUS-guided FNA of pancreatic metastases: a multicenter experience. *Gastrointest Endosc* 2005;61:689-96.
131. El Hajj II, LeBlanc JK, Sherman S, et al. Endoscopic ultrasound-guided biopsy of pancreatic metastases: a large single-center experience. *Pancreas* 2013;42:524-30.
132. Eloubeidi MA, Tamhane AR, Buxbaum JL. Unusual, metastatic, or neuroendocrine tumor of the pancreas: a diagnosis with endoscopic ultrasound-guided fine-needle aspiration and immunohistochemistry. *Saudi J Gastroenterol* 2012;18:99-105.
133. Tanaka T, Matsugu Y, Koide K, et al. Malignant lymphoma of the pancreas. *Digest Dis Sci* 1996;41:402-4.
134. Kondo T, Hayakawa T, Shibata T, et al. Pancreatic involvement by lymphoma simulates pancreatic carcinoma. *J Clin Gastroenterol* 1989;11:594-6.

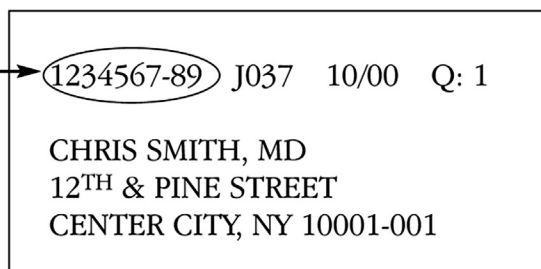
135. Lin H, Li SD, Hu XG, et al. Primary pancreatic lymphoma: report of six cases. *World J Gastroenterol* 2006;12:5064-7.
136. Sheth S, Fishman EK. Imaging of uncommon tumors of the pancreas. *Radiol Clin North Am* 2002;40:1273-87; vi.
137. Khashab M, Mokadem M, DeWitt J, et al. Endoscopic ultrasound-guided fine-needle aspiration with or without flow cytometry for the diagnosis of primary pancreatic lymphoma—a case series. *Endoscopy* 2010;42:228-31.
138. Harinck F, Konings IC, Kluijft I, et al. A multicentre comparative prospective blinded analysis of EUS and MRI for screening of pancreatic cancer in high-risk individuals. *Gut*. Epub 2015 May 18.
139. Canto MI, Hruban RH, Fishman EK, et al. Frequent detection of pancreatic lesions in asymptomatic high-risk individuals. *Gastroenterology* 2012;142:796-804; quiz e14-5.
140. Shin EJ, Canto MI. Pancreatic cancer screening. *Gastroenterol Clin North Am* 2012;41:143-57.

Access to ***Gastrointestinal Endoscopy Online*** is reserved for all subscribers!

Full-text access to ***Gastrointestinal Endoscopy Online*** is available for all subscribers. ASGE MEMBER SUBSCRIBERS: To activate your individual online subscription, please visit <http://www.asge.org> and follow the instructions. NON-MEMBER SUBSCRIBERS: To activate your individual online subscription, please visit <http://www.giejournal.org> and follow the prompts to activate your *online access*. To activate your account, you will need your subscriber account/membership number, which you can find on your mailing label (*note*: the number of digits in your subscriber account number varies from 6 to 10 digits). See the example below in which the subscriber account number has been circled:

Sample mailing label

This is your Nonmember subscriber account number →



Personal subscriptions to ***Gastrointestinal Endoscopy Online*** are for individual use only and may not be transferred. Use of ***Gastrointestinal Endoscopy Online*** is subject to agreement to the terms and conditions as indicated online.