

## The role of endoscopy in the management of patients with known and suspected colonic obstruction and pseudo-obstruction

*This is one of a series of statements discussing the use of gastrointestinal endoscopy in common clinical situations. The Standards of Practice Committee of the American Society for Gastrointestinal Endoscopy (ASGE) prepared this text. In preparing this guideline, a search of the medical literature was performed by using PubMed. Additional references were obtained from the bibliographies of the identified articles and from recommendations of expert consultants. When little or no data exist from well designed prospective trials, emphasis is given to results from large series and reports from recognized experts. Guidelines for appropriate use of endoscopy are based on a critical review of the available data and expert consensus at the time the guidelines are drafted. Further controlled clinical studies may be needed to clarify aspects of this guideline. This guideline may be revised as necessary to account for changes in technology, new data, or other aspects of clinical practice. The recommendations are based on reviewed studies and are graded on the quality of the supporting evidence (Table 1).<sup>1</sup> The strengths of individual recommendations are based both upon the aggregate evidence quality and an assessment of the anticipated benefits and harms. Weaker recommendations are indicated by phrases such as “we suggest,” whereas stronger recommendations are typically stated as “we recommend.”*

*This guideline is intended to be an educational device to provide information that may assist endoscopists in providing care to patients. This guideline is not a rule and should not be construed as establishing a legal standard of care or as encouraging, advocating, requiring, or discouraging any particular treatment. Clinical decisions in any particular case involve a complex analysis of the patient's condition and available courses of action. Therefore, clinical considerations may lead an endoscopist to take a course of action that varies from these guidelines.*

### INTRODUCTION

Endoscopy may play a role in the management of colonic obstruction from malignant and benign conditions. Colonoscopy may be required to determine the

cause of obstruction, obtain tissue for diagnosis, and provide treatment. Approximately 15% to 20% of patients with colorectal cancer present with colonic obstruction.<sup>2-6</sup> Metastatic cancer and locally advanced pelvic tumors also may cause colonic obstruction. Benign causes of obstruction include volvulus, Crohn's disease, diverticulitis, anastomotic strictures, radiation injury, ischemia, foreign bodies, and intussusception.

The present document describes the role of endoscopy in known and suspected colonic obstruction, including an update of an earlier ASGE guideline on acute colonic pseudo-obstruction (ACPO).<sup>7</sup>

### PRESENTATION AND INITIAL EVALUATION

Patients with colonic obstruction typically present with periumbilical or hypogastric pain, ranging in intensity from mild discomfort to severe pain, associated with abdominal distention. Patients with severe unremitting pain or peritoneal signs may have complete obstruction or gangrenous bowel and should be referred for surgical consultation. Endoscopy is contraindicated in these patients, because of risk of perforation from air insufflation of the distended bowel. Abdominal radiographs in colonic obstruction usually show disproportionate colonic distention proximal to the obstructing site, with air-fluid levels on upright or decubitus films.<sup>8</sup> Volvulus can often be diagnosed on plain radiographs by its characteristic findings.<sup>9</sup> Abdominal cross-sectional imaging with CT scans also may aid in the localization of obstruction and can help determine its etiology.

After partial obstruction is confirmed, intravenous fluids should be administered for volume resuscitation and correction of electrolytes, and intermittent nasogastric suction may be performed for bowel decompression. The site of obstruction then can be evaluated, either directly by endoscopy or by radiologic studies. Endoscopic evaluation of left-side colonic obstruction by flexible sigmoidoscopy or limited colonoscopy allows confirmation of the site of obstruction and treatment with anal decompression tubes, stents, or direct endoscopic decompression and requires only cleansing enemas for preparation. Endoscopic evaluation of the right side of the colon also can be helpful but may be more challenging because it may require a cautious colonoscopy bowel preparation to facilitate the examination of the entire colon in patients at higher risk for

**TABLE 1. GRADE system for rating the quality of evidence for guidelines**

Quality of evidence	Definition	Symbol
High quality	Further research is very unlikely to change our confidence in the estimate of effect	⊕⊕⊕⊕
Moderate quality	Further research is likely to have an important impact on our confidence in the estimate of effect and may change the estimate	⊕⊕⊕○
Low quality	Further research is very likely to have an important impact on our confidence in the estimate of effect and is likely to change the estimate	⊕⊕○○
Very low quality	Any estimate of effect is very uncertain	⊕○○○

Adapted from Guyatt GH, Oxman AD, Vist GE, et al, GRADE Working Group. GRADE: an emerging consensus on rating quality of evidence and strength of recommendations. *BMJ* 2008;336(7650):924-6.

perforation. If a contrast enema is performed, water-soluble contrast may be preferred over barium to avoid the risk of barium impaction at the site of obstruction or barium peritonitis in patients with unrecognized perforation. The greater mucosal detail provided by barium contrast compared with water soluble contrast is generally not necessary in this setting.

### Malignant colonic obstruction

Colonic adenocarcinoma is responsible for as much as three-fourths of all malignant colonic obstruction.<sup>10</sup> The majority of colonic adenocarcinomas causing obstruction are localized to the left side of the colon, with the sigmoid colon being the single most common location. Metastatic disease to the colon and uncommon primary colonic tumors also may cause colonic obstruction, and pelvic tumors may result in obstruction through extrinsic colonic compression or colonic invasion. Malignant colonic obstruction may be treated by using conventional surgery with resection or diversion procedures, but patients presenting with malignant obstruction often are poor surgical candidates. Urgent surgical intervention in this setting is associated with a mortality rate of >10% and morbidity up to 40%.<sup>5,11</sup> Patients treated with a diverting colostomy frequently retain the stoma indefinitely because of the discovery of metastatic disease.<sup>12-14</sup> Endoscopic alternatives to the urgent surgical management of malignant colonic obstruction include tumor ablation and the placement of either decompression tubes or self-expanding metallic stents (SEMS). A collaborative approach to patient management, including surgeons and endoscopists, is recommended to guide patient care.

**Tumor debulking.** Endoscopic laser therapy,<sup>15-21</sup> argon plasma coagulation (APC),<sup>22</sup> and snare polypectomy with or without APC<sup>23</sup> have been used to debulk obstructing colorectal tumors in patients who are unwilling to undergo surgery or are deemed to be unfit for surgery. Brunetaud et al<sup>20</sup> reported their results in 272 patients who were treated with laser for obstructing rectosigmoid cancers, with initial relief of obstructive symptoms in 85% with complications in 2%. Gevers et al<sup>16</sup> reported a case series of 117 patients with distal obstructing colorectal carcinoma treated with laser; 65% remained symptom free until death or the end of follow-up (mean 6.7 months), although a mean of 7 treatments was required. Courtney et al<sup>17</sup> studied 57 patients treated with laser; lifelong palliation was achieved in 89%, with a median of 3 treatments and major complications occurring in 5%. APC has been used to ablate obstructing tumors, but its effectiveness has been reported only in small cases series.<sup>22,23</sup>

**Transanal colonoscopic decompression tubes for malignant obstruction.** Transanal colonoscopic decompression provides another alternative to diverting colostomy. Endoscopic placement of a transanal tube for decompression of malignant colonic obstruction has been reported in several large case series.<sup>24-28</sup> Although bowel cleansing is often not possible owing to the small caliber of the tubes, the ability to decompress colonic gas can result in clinical improvement.<sup>29</sup> After transanal tube placement, decompression of the obstructed colon, with or without lavage, allowed 78% to 100% of patients to proceed directly to 1-stage surgery without need for colostomy.<sup>26,27</sup> Different tubes and techniques were used in the various case series with similar results, suggesting that the primary benefit results from the act of decompression rather than from any particular technique of tube placement or specific tube used. Despite these benefits, transanal tube placement is not routinely used at many centers. Limitations include tube dysfunction and expulsion, patient discomfort, nursing care issues, and the inability to use the tube indefinitely for palliation.

**Self-expanding metallic stents for malignant obstruction.** Endoscopic placement of colorectal stents is an effective alternative to surgical decompression for colonic obstruction.<sup>30</sup> In a pooled analysis of 54 trials, reporting on 1198 patients with malignant colorectal obstruction, SEMS placement achieved clinical success in 91%.<sup>31</sup> Similarly, SEMS placement provided relief of malignant colonic obstruction in 90% of 598 patients, pooled from 29 case series.<sup>32</sup> In the most current review of 88 articles incorporating the results of SEMS placement in 1785 patients for malignant colonic obstruction, clinical success was achieved at a median rate of 92%.<sup>33</sup> Serious complications were reported in <5% of patients in each of these 3 series. Although excellent right-side colonic SEMS placement outcomes have been reported from expert centers, data are more limited than for left-side colonic SEMS placement.<sup>34-36</sup> Two precautions emerge from these stud-

ies. First, stricture dilation before or immediately after stent placement results in a 5- to 6-fold higher rate of perforation (10%-18%) and should generally be avoided.<sup>31,32</sup> Second, covered stents may have inferior outcomes compared with uncovered stents because of a significantly higher migration rate (31% vs 3%).<sup>31</sup> Colonic SEMS placement is cost-effective compared with initial colostomy, based on data from several retrospective series.<sup>37,38</sup> Together, these analyses demonstrate that SEMS placement provides cost-effective relief of malignant colonic obstruction with an acceptable rate of complications in a broad population of patients.

**Colonic SEMS as a bridge to surgery.** In patients with malignant colonic obstruction who are candidates for surgical resection, placement of a colonic SEMS allows colonic decompression without the morbidity and mortality of urgent surgery. SEMS placement results in significantly lower complication rates, shorter hospital stays, a higher rate of primary anastomosis, and lower rates of colostomy compared with urgent surgery.<sup>33,39-41</sup> Mortality with SEMS placement is similar to that with urgent surgery,<sup>42</sup> and SEMS offers better health-related quality of life and reduced costs.<sup>43</sup> Moreover, the relief of symptoms provided by SEMS placement allows additional time to stabilize the patient, address underlying comorbid medical illnesses, perform a thorough staging evaluation of the cancer, and offers the opportunity to provide neoadjuvant therapy in patients with rectal cancer. In this way, colorectal stent placement serves as a favorable “bridge to surgery.” For those patients who appear to be surgical candidates but later are found to have widely metastatic disease, the SEMS can be left in place and a potentially permanent ostomy avoided.<sup>44</sup>

**Colonic SEMS as palliative therapy.** Colonic SEMS can also provide effective palliation for patients with malignant colonic obstruction who are recognized at initial evaluation to be poor operative candidates. In each of the three systematic reviews noted above, the outcomes of colonic SEMS placement for palliation were favorable; the median rate of clinical success was 90% to 93%, and the median rate of reobstruction was 12% to 16%.<sup>31,32,33</sup> Patients undergoing palliative SEMS placement compared with surgery had lower medical complications, shorter hospital length of stay, reduced need for colostomy,<sup>45,46</sup> more prompt initiation of chemotherapy,<sup>47</sup> and a trend toward decreased mortality.<sup>48-50</sup> Finally, colonic SEMS placement for palliation also is cost-effective compared with initial colostomy.<sup>51</sup> In recognition of these findings, recent reviews support endoscopic placement of colonic SEMS as an effective approach to palliation of patients with malignant colonic obstruction who are not candidates for definitive surgical resection.<sup>52-54</sup> However, it is important to note that one randomized clinical trial comparing endoscopic stenting to surgery for stage IV left-side colo-

rectal cancer was closed early owing to a high number of serious adverse events in the stent arm.<sup>55</sup>

Colonic SEMS also may serve for palliation of rectal cancer. Rey et al<sup>56</sup> reported successful placement of SEMS in 11 of 12 patients with obstructing rectal cancer undergoing laser therapy, and effectively reduced the requirements for laser treatment. Similarly, Hünnerbein et al achieved initial technical success in 33 out of 34 patients (97%) but advised that stent placement is contraindicated for low rectal cancer (<5 cm from anal verge), patients with incontinence, and those undergoing hyperthermia, and they did not find benefit for tumor-related symptoms of pain or bleeding.<sup>57</sup>

**Colonic SEMS for extracolonic malignancy.** There are very limited data on the use of colonic SEMS for extracolonic malignancy (ECM). Two retrospective studies show variable technical success (20%-87%) and frequent complications (33%-39%).<sup>58,59</sup> Given the variable benefit and high rate of complications from SEMS placement in these studies, alternatives to colonic SEMS should be strongly considered for patients with obstruction due to ECM.

### Benign colonic obstruction

Benign colonic obstruction may occur due to a wide variety of causes. Acute obstruction may result from colonic volvulus, diverticulitis, intussusception, and hernia. Less acute presentations of benign colonic obstruction result from strictures or extrinsic compression of the bowel. Anastomotic strictures have been reported to occur in up to 30% of patients undergoing colorectal surgery, with one recent retrospective study of 68 patients reporting symptomatic strictures in 18% of patients.<sup>60</sup> Colonic strictures can arise in patients with inflammatory bowel disease; among patients hospitalized for complications of ulcerative colitis, 59 out of 1156 patients (5%) had colorectal strictures.<sup>61</sup> Strictures may also occur after radiation therapy, diverticulitis, or ischemic colitis.<sup>62</sup> Endoscopic therapy for benign colonic strictures includes dilation, performed digitally or with balloon or rigid dilators, dilation in conjunction with steroid injection or electroincision, and placement of decompression tubes or expandable stents.

**Colonic volvulus.** Colonic volvulus occurs when the bowel twists upon itself, resulting in obstruction, venous congestion, and eventual arterial inflow obstruction to the affected segment. The most common locations for colonic volvulus include the sigmoid colon and the cecum.<sup>63</sup> Common presenting signs and symptoms include abdominal pain and tenderness, distention, and obstipation. The endoscopic appearance is often characterized by an abruptly twisted and closed lumen. Once the endoscope passes beyond this point, the bowel is typically cavernous. Endoscopic decompression with rectal tube placement has been reported to be successful in 78% of 562 patients with sigmoid volvulus.<sup>64</sup> Recurrence after nonoperative decom-

pression is common,<sup>65</sup> however, so elective surgical treatment is generally recommended after endoscopic detorsion of the bowel. Some endoscopists will leave a rectal tube in place to decrease the risk of recurrence, although the utility of this intervention is not well established.<sup>66</sup> Emergent surgery is indicated for colonic volvulus with perforation, bowel infarction, peritonitis, or failed nonoperative attempts at detorsion of the bowel. Mortality from volvulus is not uncommon, with rates of 25% to 80% reported when gangrene is present.<sup>66</sup>

Endoscopic intervention for cecal volvulus has proven to be less effective than for sigmoid volvulus. Though there have been reports of successful colonoscopic decompression of cecal volvulus, the failure rate is high.<sup>67</sup> Therefore, colonoscopy is not generally recommended and surgical management is typically preferred for cecal volvulus.

**Dilation of benign colonic strictures.** Endoscopic balloon dilation has been shown to be effective for the treatment of strictures resulting from both surgical anastomoses and inflammatory bowel disease. In two series of a total of 42 patients with symptomatic anastomotic strictures, endoscopic dilation was clinically successful in all cases, with no complications.<sup>60,68</sup>

Endoscopic balloon dilation of strictures due to inflammatory bowel disease is technically successful in 73% to 97% of patients, although the majority of patients treated with dilation experience recurrence, requiring repeated balloon dilation or surgery.<sup>69-74</sup> Other complications of dilation for inflammatory bowel disease include perforation, bleeding, and infection. Hassan et al<sup>75</sup> performed a systematic review of 13 studies including 347 patients with Crohn's disease-related strictures, comprising primarily ileocolonic anastomotic strictures (66%) and colonic strictures (13%). Technical success was reported in 86% of cases, with a mean of 2.2 dilations required per patient and long-term clinical efficacy in 58%. The rate of major complications was 2% overall, including 13 perforations. In their multivariate analysis, a stricture length  $\leq 4$  cm was associated with a fourfold increase in the odds of avoiding surgery compared with longer strictures.

Steroid injection has been used in conjunction with balloon dilation for patients with recurrent strictures to reduce the need for repeated dilation or surgery. Three retrospective case series reported favorable outcomes from steroid injection combined with endoscopic balloon dilation for the treatment of recurrent strictures.<sup>76-78</sup> Steroid treatment combined with dilation has uncertain benefit for the initial treatment of benign colonic strictures.<sup>79,80</sup>

Electroincision also has been successfully used together with balloon dilation for the treatment of anastomotic strictures in uncontrolled studies with a good safety profile.<sup>81-83</sup> Benign colonic strictures have been treated effectively by using either a precut papillotome in a study of 39 patients<sup>81</sup> or a neodymium:yttrium-aluminum-garnet laser and balloon dilation in a study of 10 patients.<sup>84</sup>

### Other therapies for benign colonic obstruction.

Transanal colonic decompression tubes have been shown to be effective for the treatment of acute benign colonic obstruction. In a case series published in 2008, 51 patients with mixed malignant and benign obstruction were treated by using decompression tubes with 100% technical success.<sup>26</sup>

Percutaneous endoscopic colostomy (PEC) has been described to treat a variety of pathology, including functional constipation, recurrent sigmoid volvulus, colonic pseudo-obstruction, and neurogenic bowel.<sup>85-87</sup> PEC of the cecum has been described in multiple small case-series and can be performed either through a combined endoscopic and radiologic approach or in a manner analogous to placement of a percutaneous endoscopic gastrostomy tube.<sup>88-92</sup> Although PEC of the cecum has had relatively favorable outcomes, results are discouraging for left-side colon PEC, with one study reporting infection in 77% of 31 patients.<sup>85</sup> This approach has typically been reserved for patients with recurrent or refractory ACPO. Use of PEC should be reserved for patients deemed to be at high risk for surgery.

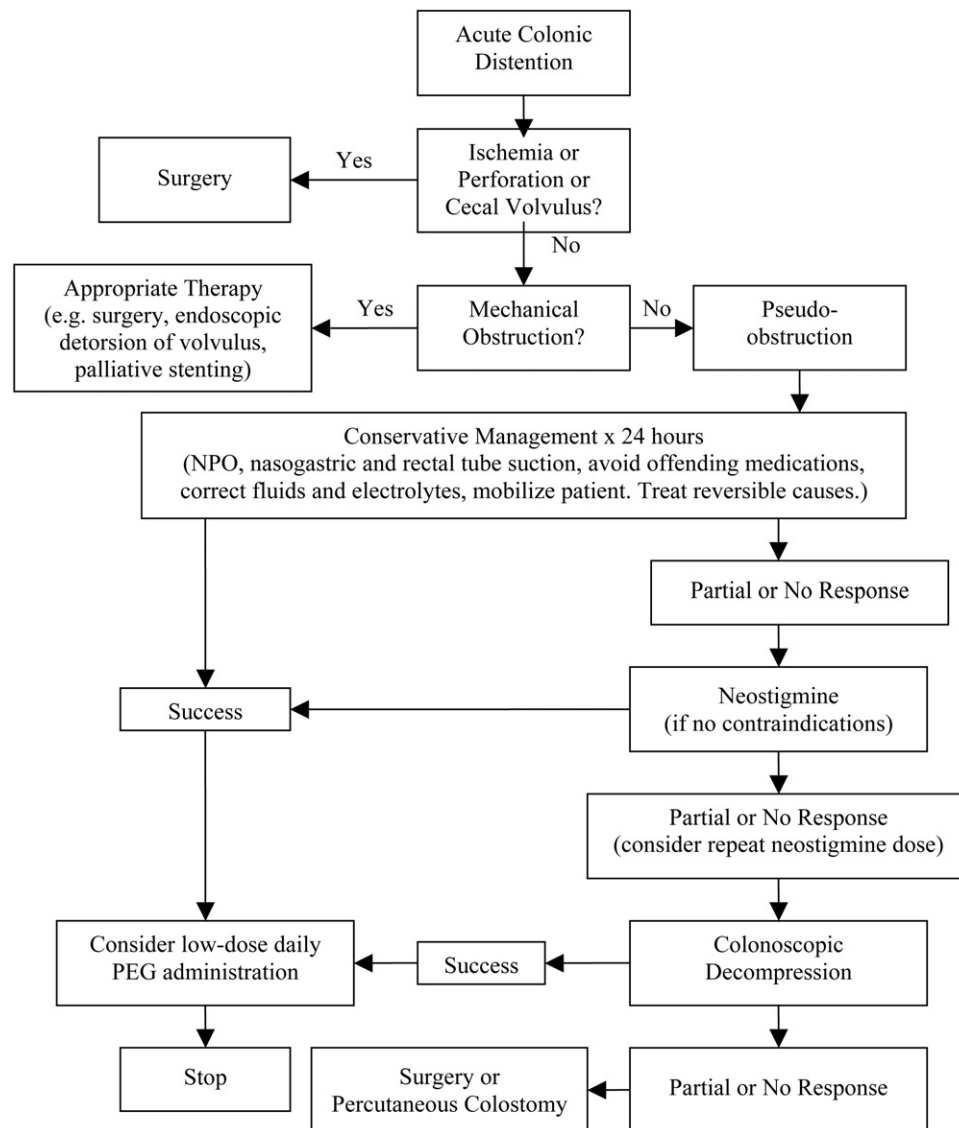
Plastic colonic stents also may be used with some success for definitive therapy of benign colonic obstruction from a variety of causes, as reported in small case series and case reports.<sup>93,94</sup> However, there are insufficient data to recommend either for or against the use of self-expanding plastic stents for benign colonic obstruction.

Colonic SEMS may serve as a bridge to surgery in patients with benign strictures requiring surgical resection. After initial bowel decompression with an SEMS, the patient can proceed to surgical resection and undergo a primary colonic anastomosis, with a lower rate of stoma formation. The high rate of stent migration and obstruction, however, may limit the role of colonic SEMS placement in benign strictures.<sup>95,96</sup> The largest series of 23 patients showed that SEMS effectively relieved obstruction in 22 out of 23 patients, but only 42% avoided creation of a stoma at time of surgery.<sup>97</sup> In the two smaller series, only 38% to 60% achieved relief of obstruction with SEMS placement.<sup>62,98</sup> Taken together, these series show that colonic SEMS placement has limited, but demonstrable, benefit as a bridge to surgery in patients with benign colonic obstruction.

Colonic SEMS placement has also been used for palliation of fistulas associated with benign strictures, radiation-induced strictures, and strictures associated with inflammatory bowel disease with mixed results.<sup>99-104</sup> However, these case reports do not provide sufficient data to determine the role of SEMS in these settings.

### Acute colonic pseudo-obstruction

Acute colonic pseudo-obstruction is characterized by massive colonic dilation in the absence of mechanical obstruction; synonyms include acute colonic ileus and Ogilvie syndrome.<sup>105-107</sup> Ischemia or perforation are the



**Figure 1.** Management of acute colonic distention.

feared complications of ACPO. Spontaneous perforation has been reported in 3% to 15% of patients, with a mortality rate of 50% or higher.<sup>108</sup> The rate of ischemia and/or perforation rapidly increases with cecal diameters of >10 to 12 cm and when the duration of distention exceeds six days.<sup>109</sup>

In evaluating a patient with signs or symptoms of suspected acute colonic dilation, mechanical obstruction should be excluded, because surgical management may be required (Fig. 1). Although initial conservative management for mechanical obstruction overlaps with the initial management of ACPO (eg, nothing by mouth, intravenous fluids, nasogastric suction), the possibility of mechanical obstruction must always be considered, particularly if there is no response to conservative management. If there is any suspicion of mechanical obstruction, a water-

soluble contrast enema of the rectum and distal colon should be obtained.

The causes of and predisposing factors associated with the development of ACPO are multiple (Table 2), and often >1 of these factors is present. Most commonly, this syndrome is associated with surgery.<sup>110,111</sup>

Based on LaPlace's law, increasing the diameter of the colon correspondingly increases the tension experienced by the colon wall. Although risk does increase with expanding dimensions, there is only a general association between risk and diameter of the colon. Animal and retrospective data suggest critical thresholds of 9 cm for the transverse colon and 12 cm for the cecum; however, many patients present with dimensions greater than this without sequelae.<sup>112</sup> Both the acuity of onset and the duration of persistent distention likely influence the risk of perfora-

**TABLE 2. Acute colonic pseudo-obstruction: causes of and predisposing factors**

Postsurgical
Intra-abdominal surgery
Other surgical procedures
Lumbar/spinal and other orthopedic, gynecologic, urologic surgery
Trauma
Retroperitoneal trauma
Spinal cord injury
Medical
Age
Sepsis
Neurologic disorders
Hypothyroidism
Viral infection (herpes, varicella zoster)
Cardiac or respiratory disorders
Electrolyte imbalances (hypokalemia, hypocalcemia, hypomagnesemia)
Medications (narcotics, tricyclic antidepressants, phenothiazides, antiparkinsonian drugs, anesthetic agents, among others)
Renal insufficiency

tion. Approximately 10% of patients have some degree of ischemia in the right colon at the time of colonoscopy. The patient's baseline state and prognosis for reversal of comorbidities should be incorporated into decisions regarding intervention for ACPO.

**Conservative therapy for ACPO.** The initial step in the management of ACPO is to evaluate for potential contributing factors and initiate corrective therapy (Table 3, Fig. 1). This should include evaluation for electrolyte and metabolic abnormalities (including phosphorous, magnesium, calcium, and thyroid functions) with parenteral correction where appropriate. Blood cultures and empiric antibiotics are indicated if sepsis is suspected clinically. Management should also include discontinuation of narcotics, anticholinergic agents, and any other possibly offending medications, exclusion of abdominal infection, mobilization out of bed, if feasible, and appropriate medical and surgical management for significant concurrent illnesses. Conservative management usually includes maintaining the patient with nothing by mouth, placement of a nasogastric tube for proximal gut decompression, aggressive use of optimal body positioning, and, often, placement of a rectal tube, with or without use of limited tap water enemas. The prone position with hips

elevated on a pillow or the knee-chest position with the hips held high often aids the spontaneous evacuation of flatus. These positions should be alternated with right and left lateral decubitus positions regularly every hour when feasible.

When there is no pain and cecal distention is not extreme, a conservative approach can be used for 24 to 48 hours before entertaining overt medical or endoscopic intervention, particularly when reversible contributory factors are identified. During this period, serial physical examinations should be performed, looking for tenderness or signs of peritonitis, and plain abdominal radiographs should be obtained every 12 to 24 hours.<sup>112</sup> Serial laboratory tests, such as complete blood cell count and electrolytes, should be monitored. The reported success of conservative management is widely variable, with rates ranging from 20% to 92%.<sup>112,113</sup> The direct benefits of any individual component of conservative management are unknown, because these recommendations have not been studied as single interventions.

**Pharmacologic therapy for ACPO.** A variety of pharmacologic agents have been tried for active reversal of ACPO. There are anecdotal reports of success when using traditional prokinetic agents such as erythromycin, metoclopramide, and cisapride. These reports suggest inconsistent responses, with only gradual improvement over 12 to 24 hours of therapy. Cisapride is generally not available at this time. Although it is relatively safe, erythromycin (250-500 mg every 6 hours) has not been evaluated in randomized studies.

The only consistently positive results for the pharmacologic treatment of ACPO have been with neostigmine, an anticholinesterase parasympathomimetic agent. Parasympathetic stimulation with this agent can also induce bradycardia, asystole, hypotension, restlessness, seizures, tremor, miosis, bronchoconstriction, hyperperistalsis, nausea, vomiting, salivation, diarrhea, and sweating. Therefore, acute administration must be accompanied by close monitoring of cardiorespiratory status, including cardiac rhythm. Toxicity is treated with atropine, which should be immediately available. Contraindications to the use of neostigmine include known hypersensitivity and mechanical urinary or intestinal obstruction. Recent myocardial infarction, acidosis, asthma, bradycardia, peptic ulcer disease, and therapy with beta-blockers are relative contraindications.

In a double-blind randomized placebo-controlled trial in 21 patients with cecal diameters of >10 cm despite 24 hours of conservative therapy, 10 out of 11 patients randomized to receive an intravenous infusion of 2 mg neostigmine over 3 to 5 minutes responded initially, and one responded after subsequent open-label retreatment.<sup>114</sup> None of 10 patients randomized to placebo experienced benefit, but all eight in whom neostigmine was openly administered subsequently responded. Two patients required atropine for symptomatic bradycardia, and

**TABLE 3. Conservative management for acute colonic pseudo-obstruction (modified from Saunders<sup>120</sup> and Saunders and Kimmey<sup>122</sup>).**

- Nothing by mouth
- Nasogastric suction
- Rectal tube decompression
- Correct fluid and electrolyte imbalances
- Limit use of narcotics, anticholinergics and other potentially aggravating medications
- Frequent positions changes
- Ambulate, if possible

there were a variety of other minor side effects. Including other open-label and retrospective studies, the use of neostigmine for ACPO has been reported in over 140 patients; these studies report colonic decompression in 87% and recurrence in 10% of patients.<sup>120</sup> Administration of a second dose of neostigmine has been associated with a clinical response in some patients failing to respond to the initial dose, although the appropriate timing and dose have not been established.<sup>114,115,120</sup>

Unfortunately, relapse of ACPO after initial response to pharmacologic or endoscopic therapy occurs in ~40% of patients.<sup>113,116</sup> Daily administration of polyethylene glycol electrolyte-balanced solution via a nasogastric tube was shown to significantly decrease the rate of relapse compared with placebo (0% vs 33%;  $P = .04$ ) in a randomized controlled trial of 30 patients who initially responded to neostigmine or colonoscopic decompression.<sup>113</sup>

**Endoscopic therapy for ACPO.** Approaches to mechanical decompression of ACPO have included radiologic placement of decompression tubes under fluoroscopic guidance, colonoscopic decompression with or without placement of a decompression tube, and cecostomy by percutaneous, endoscopic, laparoscopic, and open surgical means. Among the invasive therapeutic options, colonoscopic decompression is preferred, although the efficacy of colonoscopic decompression has not been established in randomized clinical trials.<sup>66,117,118</sup> Given the presence of pseudo-obstruction, colonoscopy for ACPO is performed without administration of oral laxatives or bowel preparation. Colonoscopy is contraindicated if overt peritonitis or perforation is present. It remains unclear whether ischemia is an absolute contraindication to proceeding with decompression. One series demonstrated that three patients with ischemia were successfully managed with colonoscopic decompression.<sup>119</sup>

In patients undergoing colonoscopy for decompression of ACPO, sedation with benzodiazepines alone is preferred, because narcotics inhibit colonic motility. Cecal intubation is not required because decompression at the

level of the proximal hepatic flexure is usually sufficient.<sup>120</sup> A guidewire may be placed through the instrument channel, followed by colonoscope withdrawal with regular suction and passage of a decompression tube over the wire under fluoroscopic guidance. Alternatively, a through-the-scope decompression tube may be placed without fluoroscopy. A large-channel colonoscope may facilitate decompression by allowing for more rapid evacuation of stool and gas and also will permit passage of a larger-diameter through-the-scope tube. The decompression tube should be placed to gravity drainage and flushed every 4 to 6 hours to prevent clogging.

Among those series of colonoscopic decompression for ACPO with more than 20 cases, success at the initial procedure, with or without tube placement, ranged from 61% to 95%, and ultimate clinical success after 1 or more procedures was 73% to 88%.<sup>120</sup> Recurrence after colonoscopic decompression has been reported to occur in ~40% of patients who do not have decompression tubes placed.<sup>121</sup> Although there are no controlled studies comparing colonoscopic decompression with or without decompression tube placement, retrospective series demonstrated lower rates of recurrence when these tubes were used.<sup>118,122</sup> A variety of approaches to tube placement have been described.<sup>66</sup> Complications of colonoscopic decompression occurred in ~3% of patients, including perforation in ~2%<sup>118,122</sup> and mortality in 1%.<sup>66</sup> There have been no trials directly comparing neostigmine with endoscopic therapy. Placement of a percutaneous endoscopic cecostomy tube as a therapeutic intervention for ACPO was discussed above.

**Surgical and radiologic decompression of ACPO.** Surgical management of ACPO, with cecostomy or colectomy, generally carries greater morbidity than endoscopic decompression. In one retrospective series of 179 patients undergoing surgery for ACPO, the morbidity and mortality rates were 30% and 6%, respectively.<sup>123</sup> Surgery is, therefore, reserved for patients who fail endoscopic and pharmacologic efforts and for those in whom exploration, lavage or drainage of the peritoneal cavity might otherwise be indicated. This includes patients with predisposing intra-abdominal processes as well as those with complications of free or contained perforation or peritonitis.<sup>124</sup>

## RECOMMENDATIONS

1. Because patients with mechanical colonic obstruction can deteriorate rapidly, we suggest that early surgical consultation be obtained for patients who may require surgical management. (⊕⊕○○)
2. We recommend against endoscopy in patients with peritoneal signs or suspicion of perforation, because these may be indicative of complete obstruction or gangrenous bowel requiring surgical intervention. Prompt surgical referral is recommended for these patients. (⊕⊕○○)

3. We suggest placement of colonic SEMS for palliation of malignant obstruction as an alternative to surgical decompression. (⊕⊕⊕⊕)  
Other options include endoscopic tumor debulking or decompression tubes.
4. We suggest that colonic SEMS be used as a “bridge to surgery” for patients with malignant obstruction who are candidates for surgery. (⊕⊕⊕⊕)
5. We suggest avoidance of dilation after colonic SEMS placement, because of the associated risk of perforation. (⊕⊕⊕⊕)
6. We suggest endoscopy for the evaluation and initial treatment of suspected sigmoid volvulus. (⊕⊕⊕⊕) There is insufficient evidence to recommend for or against the use of a decompression tube to help avoid recurrence.
7. We suggest use of colonoscopic dilation of Crohn’s disease strictures as an alternative to surgery after careful consideration of the risk/benefit ratio. (⊕⊕⊕⊕)
8. For patients undergoing endoscopic balloon dilation for recurrent benign colonic strictures, we suggest concurrent steroid injection. (⊕⊕⊕⊕)
9. We suggest that colonic SEMS may be used for treatment of patients with benign colonic strictures as a “bridge to surgery,” recognizing the significant rate of stent migration and obstruction. (⊕⊕⊕⊕)
10. We recommend conservative therapy as the preferred initial management for ACPO, including identifying and correcting potentially contributing metabolic, infectious, and pharmacologic factors. (⊕⊕⊕⊕)
11. For patients with ACPO who have failed conservative therapy, are at risk for perforation, and have no contraindications to its use, we recommend administration of neostigmine with appropriate cardiovascular monitoring. (⊕⊕⊕⊕) There is insufficient evidence to recommend for or against administration of a second dose of neostigmine if the patient fails to respond to the first dose.
12. For patients with ACPO with contraindications to neostigmine and those failing pharmacologic management, we suggest decompression with more invasive methods, typically colonoscopy with decompression tube placement. (⊕⊕⊕⊕)
13. For patients with ACPO with overt perforation or signs of peritonitis, we recommend surgical management. (⊕⊕⊕⊕)

## REFERENCES

1. Guyatt GH, Oxman AD, Vist GE, et al, GRADE Working Group. GRADE: an emerging consensus on rating quality of evidence and strength of recommendations. *BMJ* 2008;336(7650):924-6.
2. Billingsley KG, Morris AM, Dominitz JA, et al. Surgeon and hospital characteristics as predictors of major adverse outcomes following colon cancer surgery: understanding the volume-outcome relationship. *Arch Surg* 2007;142:23-31.
3. Deans GT, Krukowski ZH, Irwin ST. Malignant obstruction of the left colon. *Br J Surg* 1994;81:1270-6.
4. Serpell JW, McDermott FT, Katrivessis H, Hughes ES. Obstructing carcinomas of the colon. *Br J Surg* 1989;76:965-9.
5. Ascanelli S, Navarra G, Tonini G, et al. Early and late outcome after surgery for colorectal cancer: elective versus emergency surgery. *Tumori* 2003;89:36-41.
6. Ohman U. Prognosis in patients with obstructing colorectal carcinoma. *Am J Surg* 1982;143:742-7.
7. Eisen GM, Baron TH, Dominitz JA, et al, Standards of Practice Committee of the American Society for Gastrointestinal Endoscopy. Acute colonic pseudo-obstruction. *Gastrointest Endosc* 2002;56:789-92.
8. Levine MS. Plain film diagnosis of the acute abdomen. *Emerg Clin North Am* 1985;3:541.
9. Agrez M, Cxameron D. Radiology of sigmoid volvulus. *Dis Colon Rectum* 1973;17:527.
10. Buechter KJ, Boustany C, Caillouette R, et al. Surgical management of the acutely obstructed colon. *Am J Surg* 1988;156:163-8.
11. Riedl S, Wiebelt H, Bertmann U, et al. Post-operative complication and fatalities in surgical therapy of colon carcinoma. Results of the German multicenter study by the Colorectal Carcinoma Study Group (German). *Chirurg* 1995;66:597-606.
12. Zorcolo L, Covotta L, Carlomagno N, et al. Safety of primary anastomosis in emergency colorectal surgery. *Colorectal Dis* 2003;5:262-9.
13. Desai DC, Brennan EJ, Feilly FJ, et al. The utility of the Hartmann procedure. *Am J Surg* 1998;175:152-4.
14. Vandervoot J, Tham TCK. Colonic stents for malignant obstruction— not a bridge too far? *Gastrointest Endosc* 2006;64:921-4.
15. Adler DG, Baron TH. Stents and lasers for colonoscopic lesions. *Curr Gastroenterol Rep* 2000;2:399-405.
16. Gevers AM, Macken E, Hiele M, et al. Endoscopic laser therapy for palliation of patients with distal colorectal carcinoma: analysis of factors influencing long-term outcome. *Gastrointest Endosc* 2000;51:580-5.
17. Courtney ED, Raja A, Leicester RJ. Eight years experience of high-powered endoscopic diode laser therapy for palliation of colorectal carcinoma. *Dis Colon Rectum* 2005;48:845-50.
18. Chia YW, Ngoi SS, Goh PM. Endoscopic Nd:YAG laser in the palliative treatment of advanced low rectal carcinoma in Singapore. *Dis Colon Rectum* 1991;34:1093-6.
19. Mathus-Vliegen EM, Tytgat GN. Laser ablation and palliation in colorectal malignancy. Results of a multicenter inquiry. *Gastrointest Endosc* 1986;32:393-6.
20. Brunetaud JM, Maunoury V, Cochelard D. Lasers in rectosigmoid tumors. *Semin Surg Oncol* 1995;11:319-27.
21. Mathus-Vliegen EM, Tytgat GN. Analysis of failures and complications of neodymium:YAG laser photocoagulation in gastrointestinal tract tumors. A retrospective survey of 18 years’ experience. *Endoscopy* 1990;22:17-23.
22. Solecki R, Zajac A, Richter P, et al. Bifocal esophageal and rectal cancer palliatively treated with argon plasma coagulation. *Surg Endosc* 2004;18:346.
23. Baumhoer D, Armbrust T, Ramadori G. Nonsurgical treatment of the primary tumor in four consecutive cases of metastasized colorectal carcinoma. *Endoscopy* 2005;37:1232-6.
24. Lelcuk S, Klausner JM, Merhav A, et al. Endoscopic decompression of acute colonic obstruction. *Ann Surg* 1986;203:292-4.
25. Tanaka T, Furukawa A, Murata K, et al. Endoscopic transanal decompression with a drainage tube for acute colonic obstruction. *Dis Colon Rectum* 2001;44:418-22.
26. Fischer A, Schrag HJ, Goos M, et al. Transanal endoscopic tube decompression of acute colonic obstruction: experience with 51 cases. *Surg Endosc* 2008;22:683-8.
27. Horiuchi A, Maeyama H, Ochi Y, et al. Usefulness of Dennis colorectal tube in endoscopic decompression of acute, malignant colonic obstruction. *Gastrointest Endosc* 2001;54:229-32.
28. Horiuchi A, Nakayama Y, Tanaka N, et al. Acute colorectal obstruction treated by means of transanal drainage tube: effectiveness before surgery and stenting. *Am J Gastroenterol* 2005;100:2765-70.



29. Frech EJ, Adler DG. Endoscopic therapy for malignant bowel obstruction. *J Support Oncol* 2007;5:303-10, 319.
30. Tierney W, Chuttani R, Croffie J, et al. Enteral stents. *Gastrointest Endosc* 2006;63:920-6.
31. Sebastian S, Johnston S, Geoghegan T, et al. Pooled analysis of the efficacy and safety of self-expanding metal stenting in malignant colorectal obstruction. *Am J Gastroenterol* 2004;99:2051-7.
32. Khot UP, Lang AW, Murali K, et al. Systematic review of the efficacy and safety of colorectal stents. *Br J Surg* 2002;89:1096-102.
33. Watt A, Faragher I, Griffin T, et al. Self-expanding metallic stents for relieving malignant colorectal obstruction: a systemic review. *Ann Surg* 2007;246:24-30.
34. Repici A, Adler DG, Gibbs CM, et al. Stenting of the proximal colon in patients with malignant large bowel obstruction: techniques and outcomes. *Gastrointest Endosc* 2007;66:940-4.
35. Shim CS, Cho JY, Jung IS, et al. Through-the-scope double colonic stenting in the management of inoperable proximal malignant colonic obstruction: a pilot study. *Endoscopy* 2004;36:426-31.
36. Campbell K, Hussey JK, Eremin O. Expandable metal stent application in obstructing carcinoma of the proximal colon: report of a case. *Dis Colon Rectum* 1997;40:1391-1.
37. Blinkert CA, Ledermann H, Jost R, et al. Acute colonic obstruction: clinical aspects and cost-effectiveness of preoperative and palliative treatment with self-expanding metallic stents—a preliminary report. *Radiology* 1998;206:199-204.
38. Osman HS, Rashid HI, Sathananthan N, et al. The cost-effectiveness of self-expanding metal stents in the management of malignant left-sided large bowel obstruction. *Colorectal Dis* 2000;2:233-7.
39. Morino M, Bertello A, Garbarini A, et al. Malignant colonic obstruction managed by endoscopic stent decompression followed by laparoscopic resections. *Surg Endosc* 2002;16:1483-7.
40. Balague C, Targarona EM, Sainz S, et al. Minimally invasive treatment for obstructive tumors of the left colon: endoluminal self-expanding metal stent and laparoscopic colectomy. Preliminary results. *Dig Surg* 2004;21:282-6.
41. Olmi S, Scaini A, Cesana G, et al. Acute colonic obstruction: endoscopic stenting and laparoscopic resection. *Surg Endosc* 2007;21:2100-4.
42. Tilney HS, Lovegrove RE, Purkayastha S, et al. Comparison of colonic stenting and open surgery for malignant large bowel obstruction. *Surg Endosc* 2007;21:225-33.
43. Govindarajan A, Naimark D, Coburn N, et al. Use of colonic stents in emergent malignant left colonic obstruction: a Markov chain Monte Carlo decision analysis. *Dis Colon Rectum* 2007;50:1811-24.
44. Repici A, Giuseppe D, Luigiano C, et al. WallFlex colonic stent placement for management of malignant colonic obstruction: a prospective study at two centers. *Gastrointest Endosc* 2008;67:77-84.
45. Law WL, Choi HK, Chu KW. Comparison of stenting with emergency surgery as palliative treatment for obstructing primary left-sided colorectal cancer. *Br J Surg* 2003;90:1429-33.
46. Fiori E, Lamazza A, De Cesare A, et al. Palliative management of malignant rectosigmoidal obstruction. Colostomy vs. endoscopic stenting. A randomized prospective trial. *Anticancer Res* 2004;24:265-8.
47. Karoui M, Charachon A, Delbaldo C, et al. Stents for palliation of obstructive metastatic colon cancer: impact on management and chemotherapy administration. *Arch Surg* 2007;142:619-23.
48. Breitenstein S, Rickenbacher A, Berdajs D, et al. Systemic evaluation of surgical strategies for acute malignant left-sided colonic obstruction. *Br J Surg* 2007;94:1451-60.
49. Siddiqui A, Khandelwal N, Anthony T, et al. Colonic stent versus surgery for the management of acute malignant colonic obstruction: a decision analysis. *Alimen Pharmacol Ther* 2007;26:1379-86.
50. Targownik LE, Spiegel BM, Sack J, et al. Colonic stent vs. emergency surgery for management of acute left-sided malignant colonic obstruction: a decision analysis. *Gastrointest Endosc* 2004;60:865-74.
51. Xinopoulos D, Dimitroulopoulos D, Theodosopoulos T, et al. Stenting or stoma creation for patients with inoperable malignant colonic obstructions? Results of a study and cost-effectiveness analysis. *Surg Endosc* 2004;18:421-6.
52. Watt AM, Faragher IG, Griffin TT, et al. Self-expanding metallic stents for relieving malignancy colorectal obstruction: a systemic review. *Ann Surg* 2007;246:24-30.
53. Dionigi G, Villa F, Rovera F, et al. Colonic stenting for malignant disease: review of literature. *Surg Oncology* 2007;16:S153-5.
54. Baron TH. Expandable gastrointestinal stents. *Gastroenterol* 2007;133:1407-11.
55. van Hooft JE, Fockens P, Marinelli AW, et al. Dutch Colorectal Stent Group. Early closure of a multicenter randomized clinical trial of endoscopic stenting versus surgery for stage IV left-sided colorectal cancer. *Endoscopy* 2008;40:184-91.
56. Rey JF, Romanczyk T, Greff M. Metal stents for palliation of rectal carcinoma: a preliminary report on 12 patients. *Endoscopy* 1995;27:501-4.
57. Hünerbein M, Krause M, Moesta KT, et al. Palliation of malignant rectal obstruction with self-expanding metal stents. *Surgery* 2005;137:42-7.
58. Keswani RN, Azar RR, Edmundowicz SA, et al. Stenting for malignant colonic obstruction: a comparison of efficacy and complications in colonic versus extracolonic malignancy. *Gastrointest Endosc* 2009;69:675-80.
59. Shin SJ, Kim TI, Kim BC, et al. Clinical application of self-expandable metallic stent for treatment of colorectal obstruction caused by extrinsic invasive tumors. *Dis Colon Rectum* 2008;51:578-83.
60. Ambrosetti P, Francis K, De Peyer R, et al. Colorectal anastomotic stenosis after elective laparoscopic sigmoidectomy for diverticular disease: a prospective evaluation of 68 patients. *Dis Colon Rectum* 2008;51:1345-9.
61. Gumaste V, Sachar DB, Greenstein AJ. Benign and malignant colorectal strictures in ulcerative colitis. *Gut* 1992;33:938-41.
62. Paul L, Pinto I, Gomez H, et al. Metallic stents in the treatment of benign diseases of the colon: preliminary experience in 10 cases. *Radiology* 2002;223:715-22.
63. Ballantyne GH, Brandner MD, Beart RW Jr, et al. Volvulus of the colon. Incidence and mortality. *Ann Surg* 1985;202:83-92.
64. Oren D, Atamanalp SS, Aydinli B, et al. An algorithm for the management of sigmoid colon volvulus and the safety of primary resection: experience with 827 cases. *Dis Colon Rectum* 2007;50:489-97.
65. Ballantyne GH. Review of sigmoid volvulus: history and results of treatment. *Dis Colon Rectum* 1982;25:494-501.
66. Kahi CJ, Rex DK. Bowel obstruction and pseudo-obstruction. *Gastroenterol Clin North Am* 2003;32:1229-47.
67. Madiba TE, Thomson SR. The management of cecal volvulus. *Dis Colon Rectum* 2002;45:264-7.
68. Di Giorgio P, De Luca L, Rivellini G, et al. Endoscopic dilation of benign colorectal anastomotic stricture after low anterior resection: A prospective comparison study of two balloon types. *Gastrointest Endosc* 2004;60:347-50.
69. Dear KL, Hunter JO. Colonoscopic hydrostatic balloon dilatation of Crohn's strictures. *J Clin Gastroenterol* 2001;33:315-8.
70. Nomura E, Takagi S, Kikuchi T, et al. Efficacy and safety of endoscopic balloon dilation for Crohn's strictures. *Dis Colon Rectum* 2006;49(10 Suppl):S59-67.
71. Ferlitsch A, Reinisch W, Püspök A, et al. Safety and efficacy of endoscopic balloon dilation for treatment of Crohn's disease strictures. *Endoscopy* 2006;38:483-7.
72. Thomas-Gibson S, Brooker JC, et al. Colonoscopic balloon dilation of Crohn's strictures: a review of long-term outcomes. *Eur J Gastroenterol Hepatol* 2003;15:485-8.
73. Couckuyt H, Gevers AM, Coremans G, et al. Efficacy and safety of hydrostatic balloon dilatation of ileocolonic Crohn's strictures: a prospective long-term analysis. *Gut* 1995;36:577-80.
74. Singh VV, Draganov P, Valentine J. Efficacy and safety of endoscopic balloon dilation of symptomatic upper and lower gastrointestinal Crohn's disease strictures. *J Clin Gastroenterol* 2005;39:284-90.

75. Hassan C, Zullo A, De Francesco V, et al. Systematic review: endoscopic dilatation in Crohn's disease. *Aliment Pharmacol Ther* 2007;26:1457-64.
76. Lavy A. Triamcinolone improves outcome in Crohn's disease strictures. *Dis Colon Rectum* 1997;40:184-6.
77. Ramboer C, Verhamme M, Dhondt E, et al. Endoscopic treatment of stenosis in recurrent Crohn's disease with balloon dilation combined with local corticosteroid injection. *Gastrointest Endosc* 1995;42:252-5.
78. Lucha PA, Fticsar JE, Francis MJ. The strictured anastomosis: successful treatment by corticosteroid injections—report of three cases and review of the literature. *Dis Colon Rectum* 2005;48:862-5.
79. East JE, Brooker JC, Rutter MD, et al. A pilot study of intrastricture steroid versus placebo injection after balloon dilatation of Crohn's strictures. *Clin Gastroenterol Hepatol* 2007;5:1065-69.
80. Brooker JC, Beckett CG, Saunders BP, et al. Long-acting steroid injection after endoscopic dilation of anastomotic Crohn's strictures may improve the outcome: a retrospective case series. *Endoscopy* 2003;35:333-7.
81. Brandimarte G, Tursi A, Gasbarrini G. Endoscopic treatment of benign anastomotic colorectal stenosis with electrocautery. *Endoscopy* 2000;32:461-3.
82. Truong S, Willis S, Schumpelick V. Endoscopic therapy of benign anastomotic strictures of the colorectum by electroincision and balloon dilatation. *Endoscopy* 1997;29:845-9.
83. Hagiwara A, Togawa T, Yamasaki J, et al. Endoscopic incision and balloon dilatation for cicatricial anastomotic strictures. *Hepatogastroenterology* 1999;46:997-9.
84. Luck A, Chapuis P, Sinclair G, et al. Endoscopic laser stricturotomy and balloon dilatation for benign colorectal strictures. *Aust N Z J Surg* 2001;71:594-7.
85. Cowlam S, Watson C, Ellringham M, et al. Percutaneous endoscopic colostomy of the left side of the colon. *Gastrointest Endosc* 2007;65:1007-14.
86. Baraza W, Brown S, McAlindon M, et al. Prospective analysis of percutaneous endoscopic colostomy at a tertiary referral centre. *Br J Surg* 2007;94:1415-20.
87. Bertolini D, De Saussure P, Chilcott M, et al. Severe delayed complication after percutaneous endoscopic colostomy for chronic intestinal pseudo-obstruction: a case report and review of the literature. *World J Gastroenterol* 2007;13:2255-7.
88. Lynch CR, Jones RG, Hilden K, et al. Percutaneous endoscopic cecostomy in adults: a case series. *Gastrointest Endosc* 2006;64:279-82.
89. Ramage JI Jr, Baron TH. Percutaneous endoscopic cecostomy: a case series. *Gastrointest Endosc* 2003;57:752-5.
90. Chevallier P, Marcy PY, Francois E, et al. Controlled transperitoneal percutaneous cecostomy as a therapeutic alternative to the endoscopic decompression for Ogilvie's syndrome. *Am J Gastroenterol* 2002;97:471-4.
91. vanSonnenberg E, Varney RR, Casola G, et al. Percutaneous cecostomy for Ogilvie syndrome: laboratory observations and clinical experience. *Radiology* 1990;175:679-82.
92. Ganc AJ, Netto AJ, Morrell AC, et al. Transcolonoscopic extraperitoneal cecostomy. A new therapeutic and technical proposal. *Endoscopy* 1988;20:309-12.
93. García-Cano J. Dilation of benign strictures in the esophagus and colon with the polyflex stent: a case series study. *Dig Dis Sci* 2008;53:341-6.
94. Lykke J, Meisner S. Treatment of benign postoperative anastomotic strictures of the colon and rectum with self-expanding coated plastic stents. *Ugeskr Laeger* 2008;170:1255.
95. Baron TH. Colonic stenting: technique, technology, and outcomes for malignant and benign disease. *Gastrointest Endosc Clin North Am* 2003;5:182-90.
96. Forshaw JF, Sankarajah D, Stewart M, et al. Self-expanding metallic stents in the treatment of benign colorectal disease: indications and outcomes. *Colorectal Dis* 2005;8:102-111.
97. Small AJ, Young-Fadok TM, Baron TH. Expandable metal stent placement for benign colorectal obstruction: outcomes for 23 cases. *Surg Endosc* 2008;22:454-62.
98. Meisner S, Hensler M, Knop FK, et al. Self-expanding metal stents for colonic obstruction: experiences from 104 procedures in a single center. *Dis Colon Rectum* 2004;47:444-50.
99. Jeyarajah AR, Sheperd JH, Fairclough PD, et al. Effective palliation of a colovaginal fistula using a self-expanding metal stent. *Gastrointest Endosc* 1997;46:367-9.
100. Fernandez LR, Pinto I, Maillou C, et al. Rectovesical fistula treated by covered self-expanding prosthesis: report of a case. *Dis Colon Rectum* 1999;42:812-5.
101. Yates MR, Baron TH. Treatment of a radiation-induced sigmoid stricture with an expandable metal stent. *Gastrointest Endosc* 1999;50:422-5.
102. Law WL, Choi HK, Chu KW, et al. Radiation stricture of rectosigmoid treated with self-expanding metallic stent. *Surg Endosc* 2002;16:1105-10.
103. Dafnis G. Repeated coaxial colonic stenting in the palliative management of benign colonic obstruction. *Eur J Gastroenterol Hepatol* 2007;19:83-6.
104. Cascales-Sanchez P, Garcia-Olma D, Julia-Molla E. Long-term expandable stent as definitive treatment for benign rectal stenoses. *Br J Surg* 1997;84:840-1.
105. Vanek VW, Al-Salti M. Acute pseudo-obstruction of the colon (Ogilvie's syndrome). An analysis of 400 cases. *Dis Colon Rectum* 1986;29:203-10.
106. Dorudi S, Berry AR, Kettlewell MG. Acute colonic pseudo-obstruction. *Br J Surg* 1992;79:99-103.
107. Vantrappen G. Acute colonic pseudo-obstruction. *Lancet* 1993;341:152-3.
108. Rex DK. Colonoscopy and acute colonic pseudo-obstruction. *Gastrointest Endosc Clin North Am* 1997;7:499-508.
109. Johnson CD, Rice RP, Kelvin FM, et al. The radiologic evaluation of gross cecal distension: emphasis on cecal ileus. *AJR Am J Roentgenol* 1985;145:1211-7.
110. Caner H, Bavbek M, Albayrak A, et al. Ogilvie's syndrome as a rare complication of lumbar disc surgery. *Can J Neurol Sci* 2000;27:77-8.
111. O'Malley KJ, Flechner SM, Kapoor A, et al. Acute colonic pseudo-obstruction (Ogilvie's syndrome) after renal transplantation. *Am J Surg* 1999;177:492-6.
112. Sloyer AF, Panella VS, Demas BE, et al. Ogilvie's syndrome. Successful management without colonoscopy. *Dig Dis Sci* 1988;33:1391-6.
113. Loftus CG, Harewood GC, Baron TH. Assessment of predictors of response to neostigmine for acute colonic pseudo-obstruction. *Am J Gastroenterol* 2002;97:3118-22.
114. Ponc RJ, Saunders MD, Kimmey MB. Neostigmine for the treatment of acute colonic pseudo-obstruction. *N Engl J Med* 1999;341:137-41.
115. Abeyta BJ, Albrecht RM, Schermer CR. Retrospective study of neostigmine for the treatment of acute colonic pseudo-obstruction. *Am Surg* 2001;67:265-8; discussion 268-9.
116. Sgouros SN, Vlachogiannakos J, Vassiliadis K, et al. Effect of polyethylene glycol electrolyte balanced solution on patients with acute colonic pseudo obstruction after resolution of colonic dilation: a prospective, randomized, placebo controlled trial. *Gut* 2006;55:638-42.
117. Jetmore AB, Timmcke AE, Gathright JB Jr, et al. Ogilvie's syndrome: colonoscopic decompression and analysis of predisposing factors. *Dis Colon Rectum* 1992;35:1135-42.
118. Geller A, Petersen BT, Gostout CJ. Endoscopic decompression for acute colonic pseudo-obstruction. *Gastrointest Endosc* 1996;44:144-50.
119. Fiorito JJ, Schoen RE, Brandt LJ. Pseudo-obstruction associated with colonic ischemia: successful management with colonoscopic decompression. *Am J Gastroenterol* 1991;86:1472-6.
120. Saunders MD. Acute colonic pseudo-obstruction. *Best Pract Res Clin Gastroenterol* 2007;21:671-87.
121. Rex DK. Colonoscopy and acute colonic pseudo-obstruction. *Gastrointest Endosc Clin N Am* 1997;7:499-508.

122. Saunders MD, Kimmey MB. Systematic review: acute colonic pseudo-obstruction. *Aliment Pharmacol Ther* 2005;22:917-25.
123. Vanek VW, Al-Salti M. Acute pseudo-obstruction of the colon (Ogilvie's syndrome). An analysis of 400 cases. *Dis Colon Rectum* 1986; 29:203-10.
124. Duh QY, Way LW. Diagnostic laparoscopy and laparoscopic cecostomy for colonic pseudo-obstruction. *Dis Colon Rectum* 1993;36:65-70.

---

Prepared by:

ASGE STANDARDS OF PRACTICE COMMITTEE

M. Edwyn Harrison

Michelle A. Anderson

Vasu Appalaneni

Subhas Banerjee

Tamir Ben-Menachem

Brooks D. Cash

Robert D. Fanelli

Laurel Fisher

Norio Fukami

Seng-Ian Gan

Steven O. Ikenberry

Rajeev Jain

Khalid Khan

Mary Lee Krinsky

John T. Maple

Bo Shen

Trina Van Guilder

Todd H. Baron (Former Chair)

Jason A. Dominitz (Current Chair)

This document is a product of the Standards of Practice Committee. This document was reviewed and approved by the Governing Board of the American Society for Gastrointestinal Endoscopy.

---

### **GIE on Facebook**

GIE now has a Facebook page. Fans will receive news, updates, and links to author interviews, podcasts, articles, and tables of contents. Search on Facebook for "GIE: Gastrointestinal Endoscopy" and become a fan.